

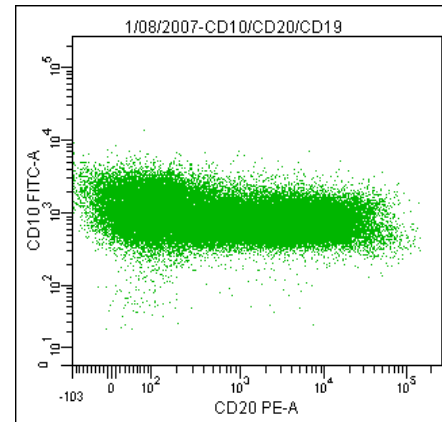
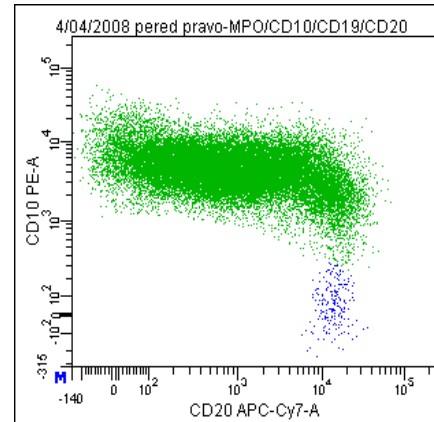
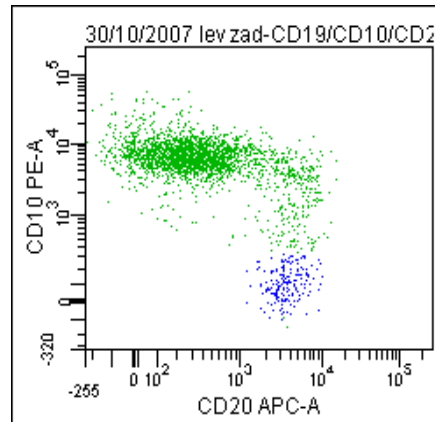
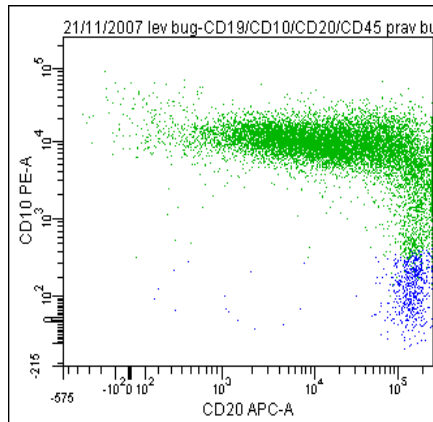
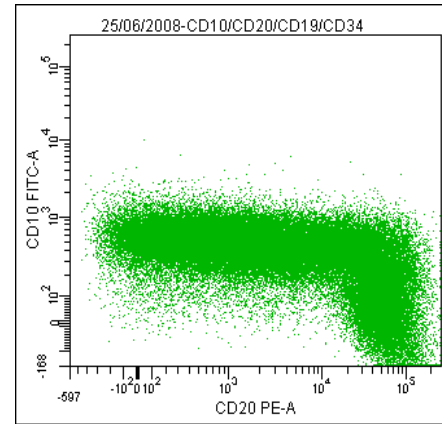
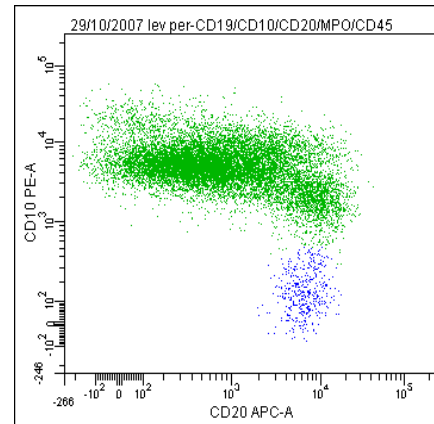
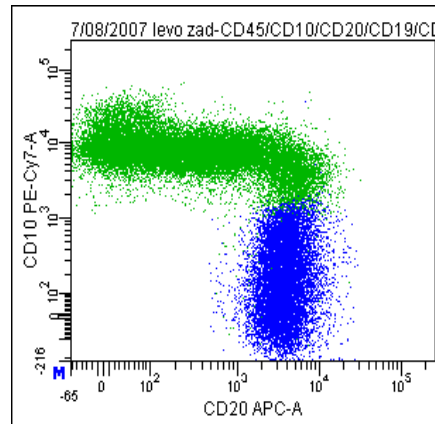
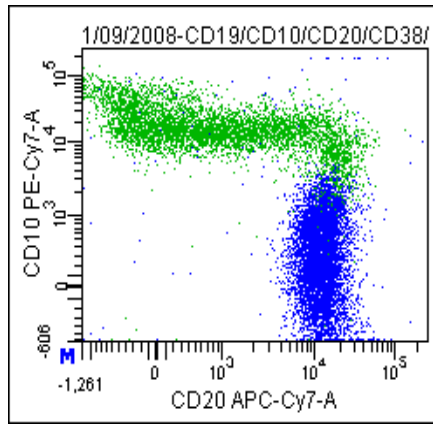
**А.М. Попов**

# **Практические аспекты диагностики ОЛ**

**Национальный Научно-Практический Центр  
Детской Гематологии, Онкологии и Иммунологии им. Дмитрия Рогачева  
Москва, Россия**

**Опухолевые или регенераторные бласты?**

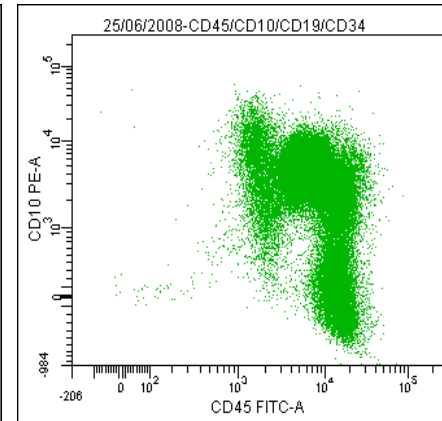
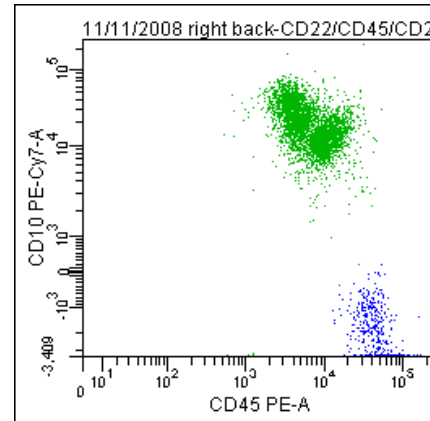
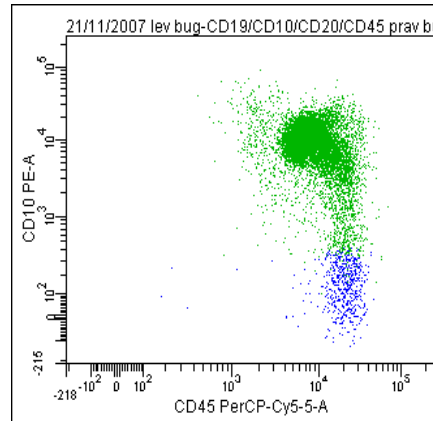
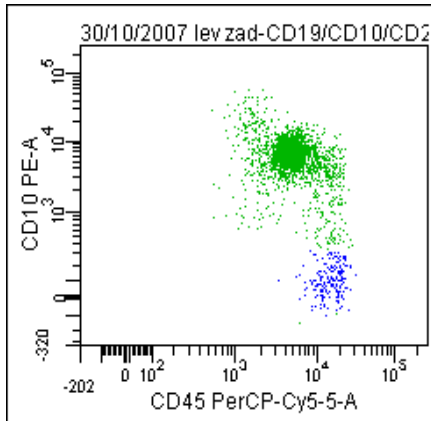
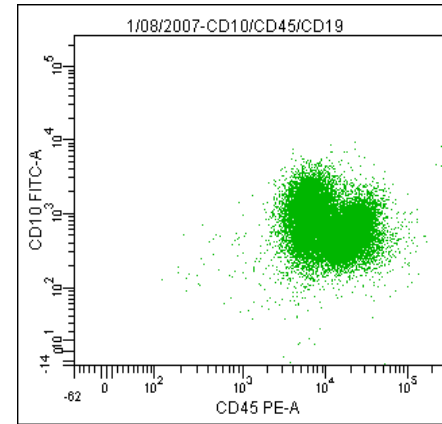
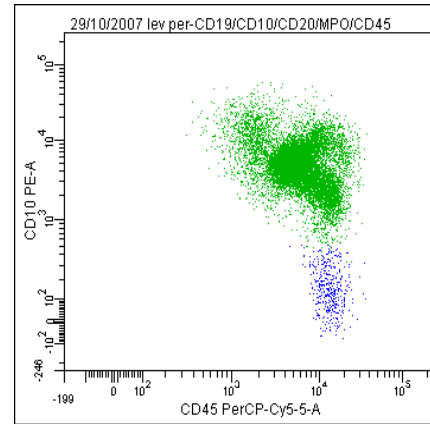
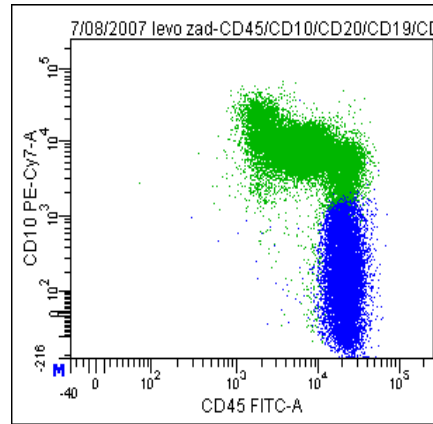
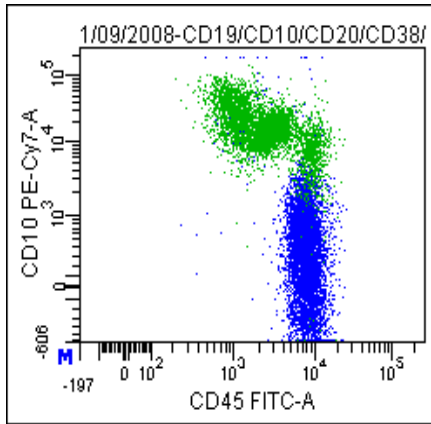
# Нормальное созревание В-лимфоцитов



CD20

CD10

# Нормальное созревание В-лимфоцитов

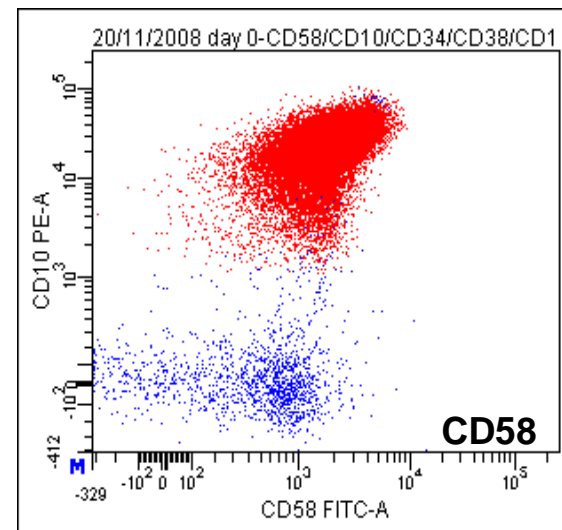
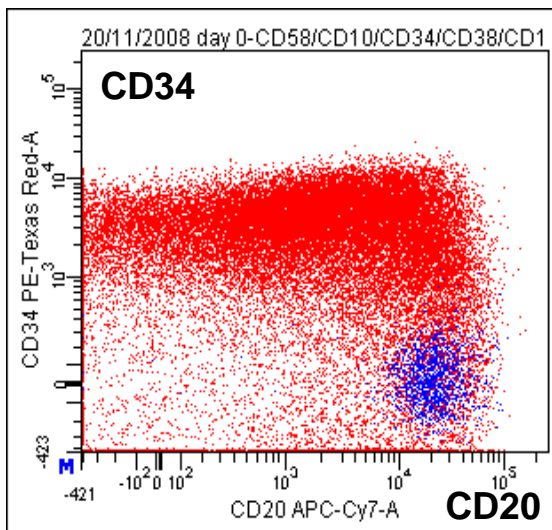
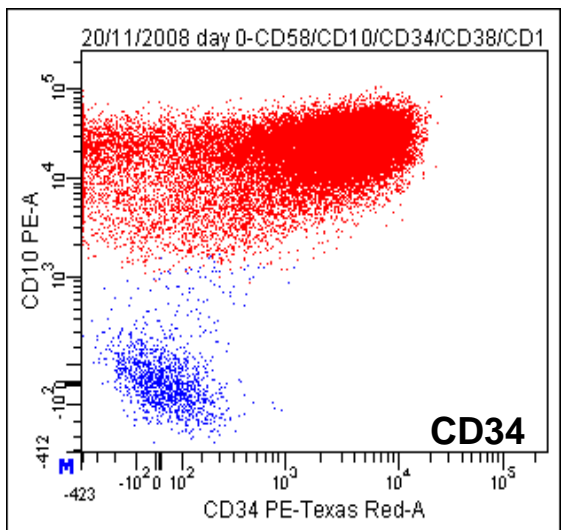
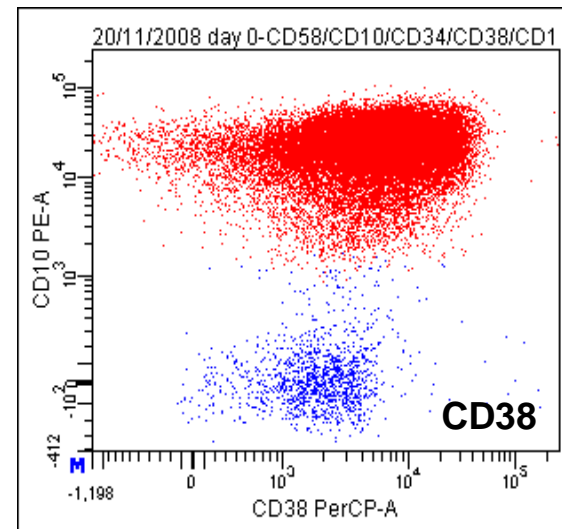
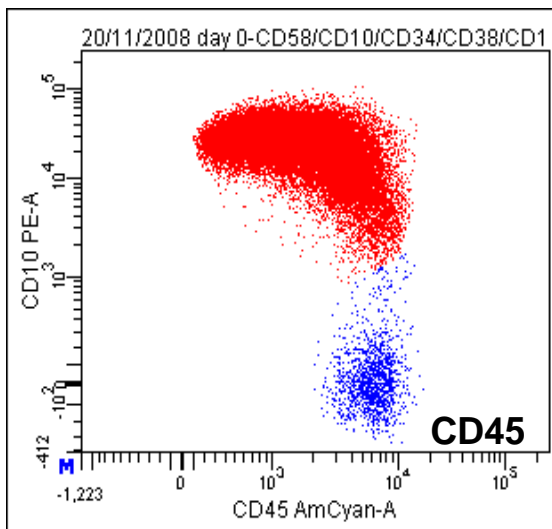
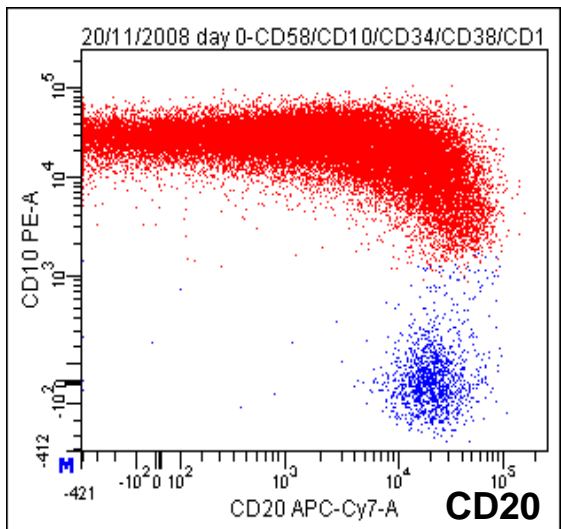


CD45

CD10

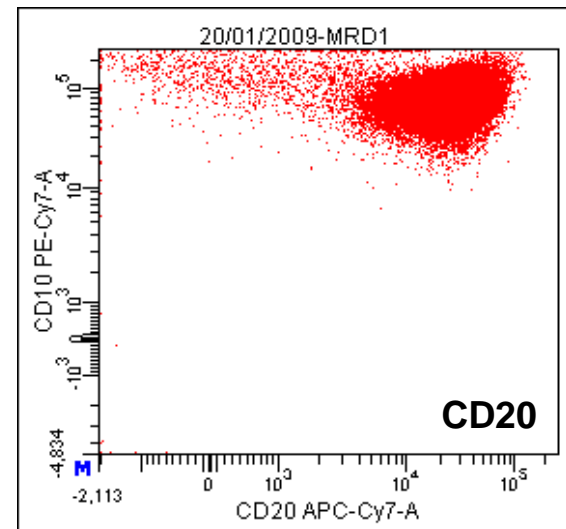
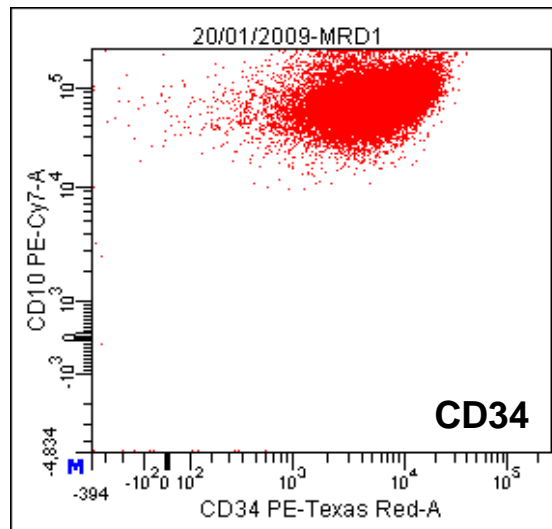
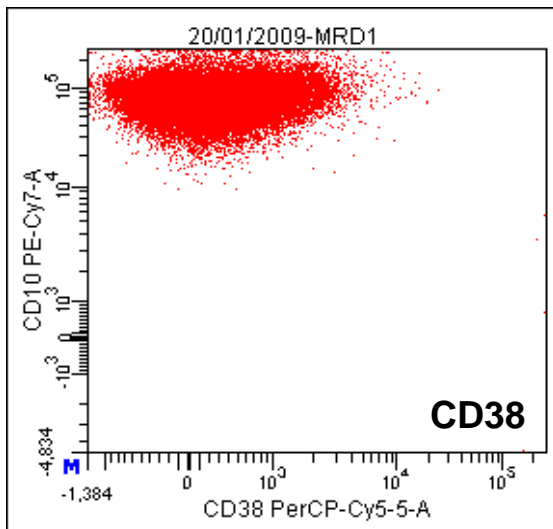
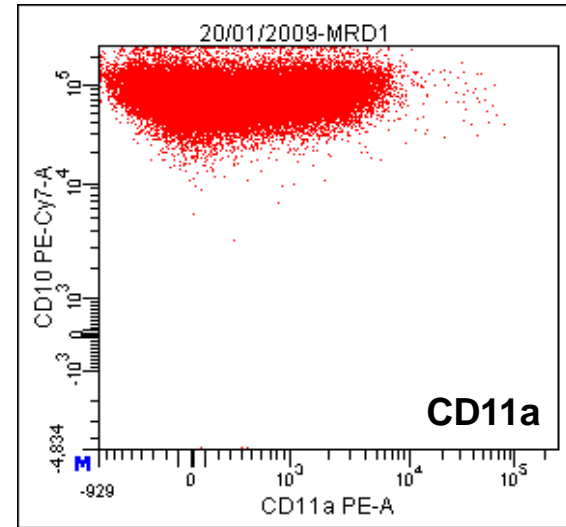
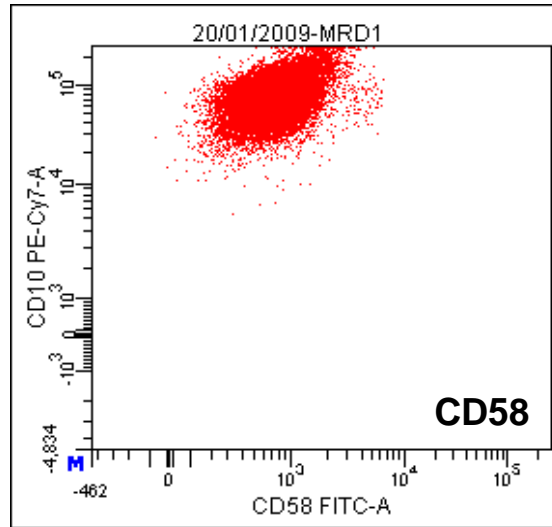
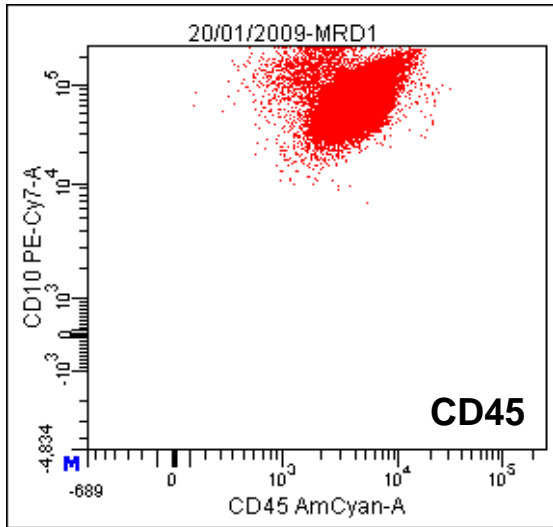
# Пациентка С.

CD10



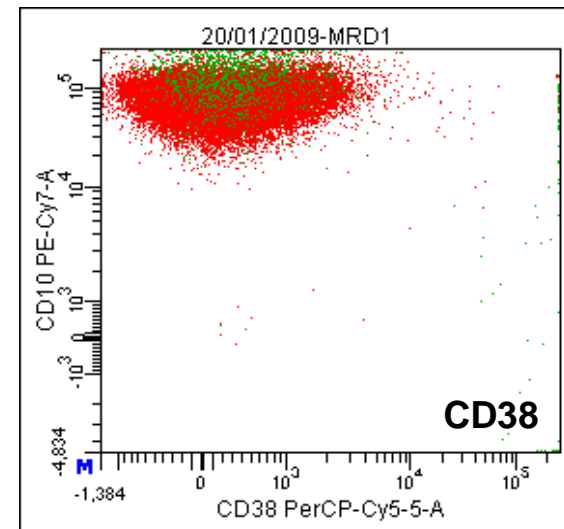
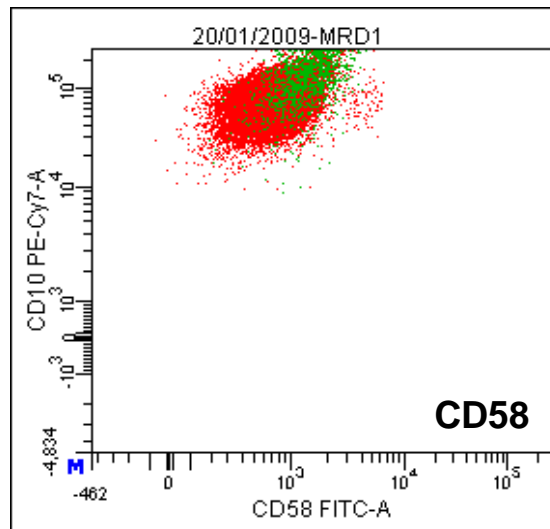
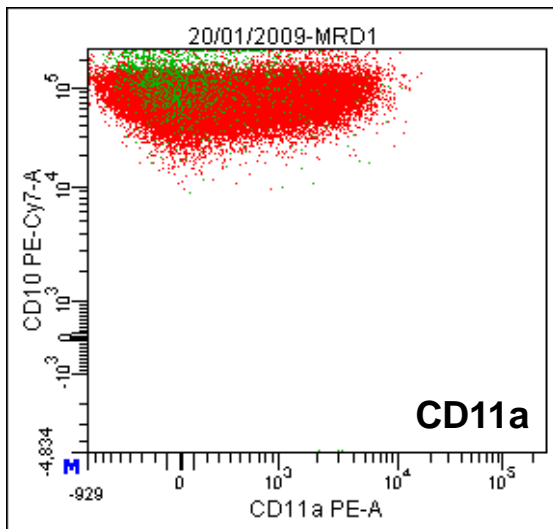
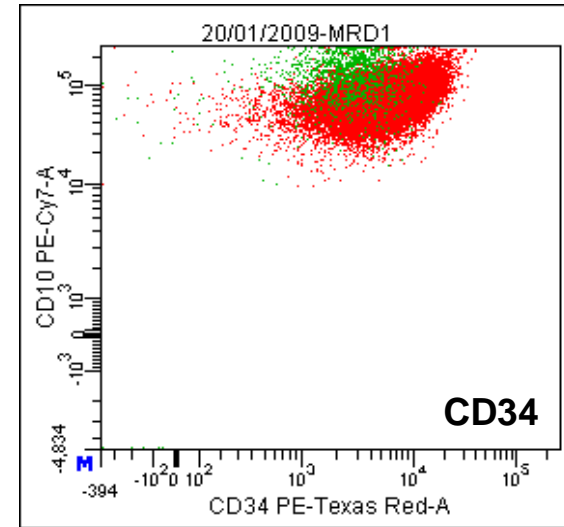
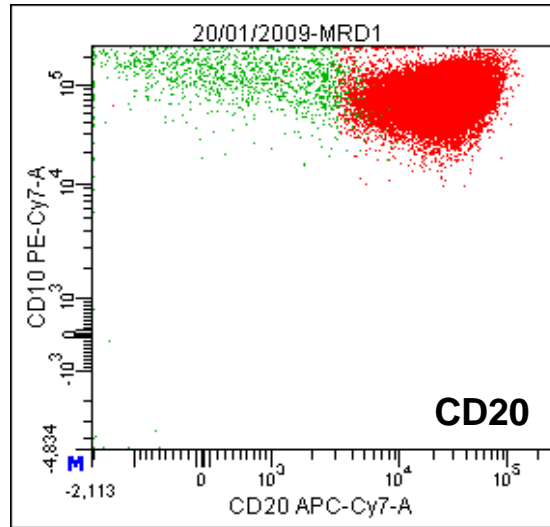
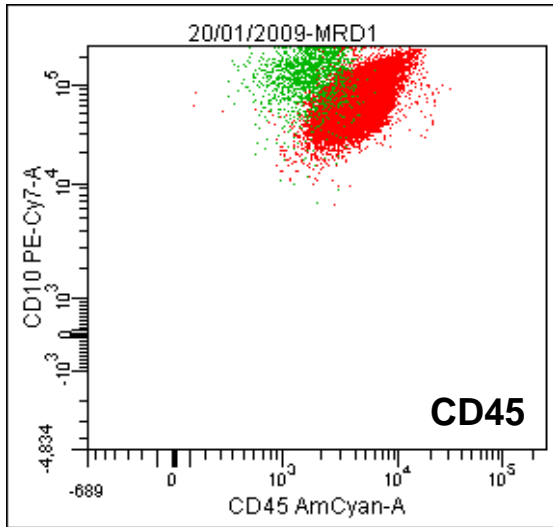
# Пациент Б.

**CD10**

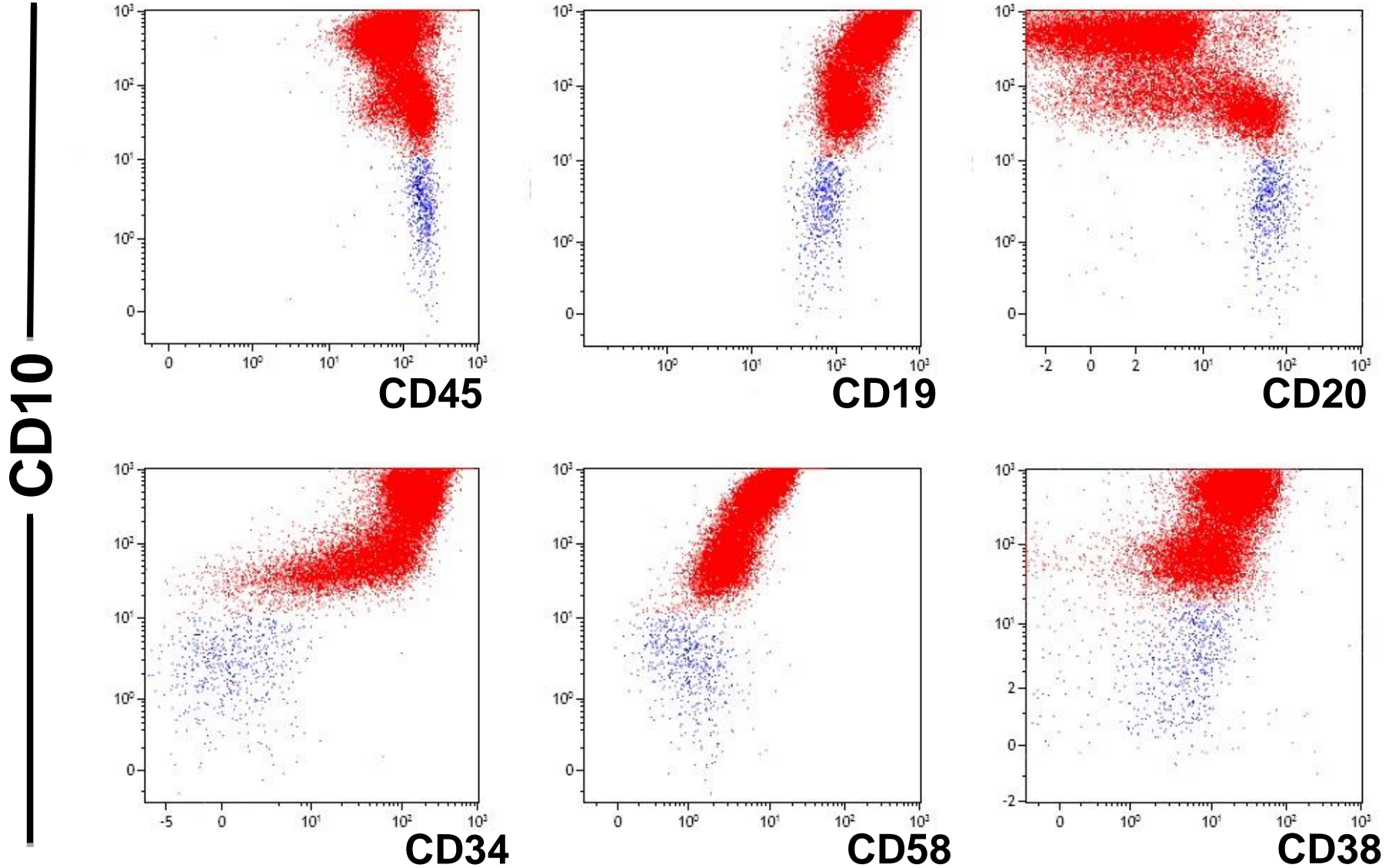


# Пациент Б.

CD10



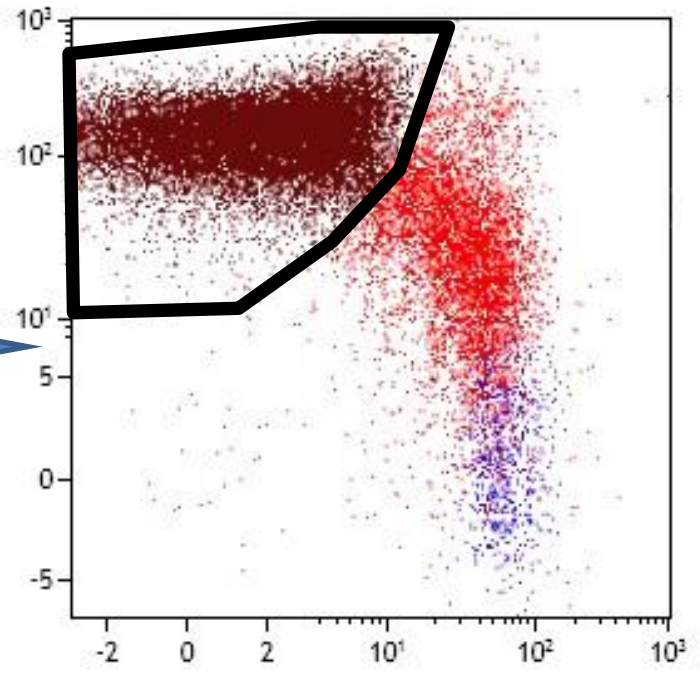
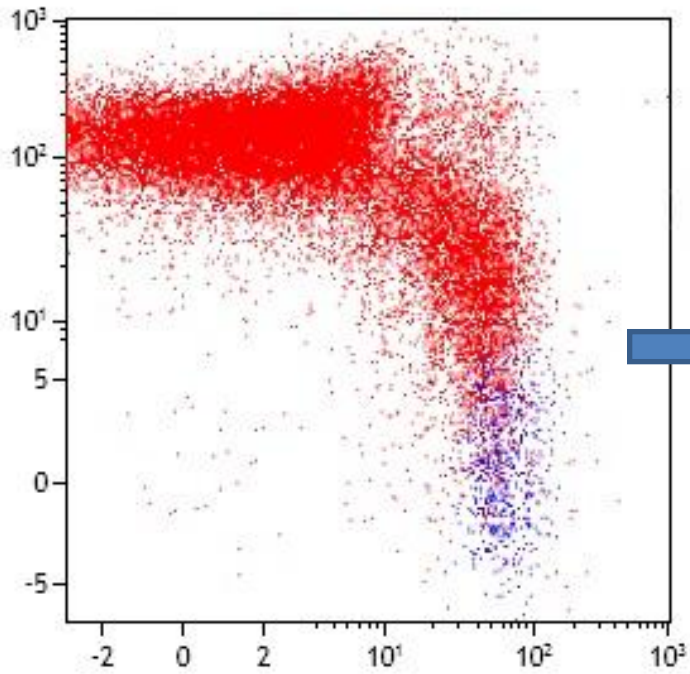
# Пациент П.





# Пациент П.

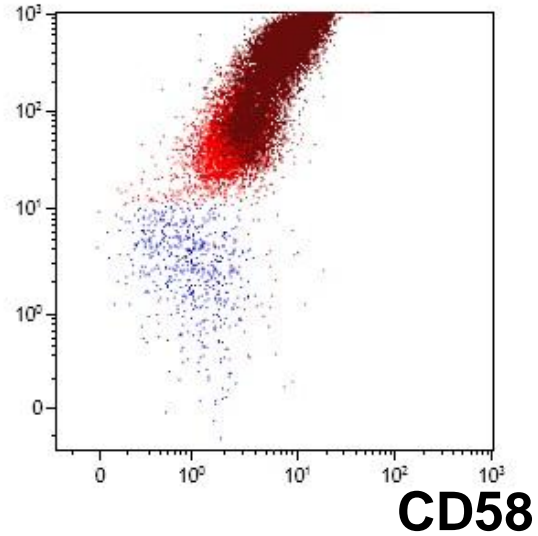
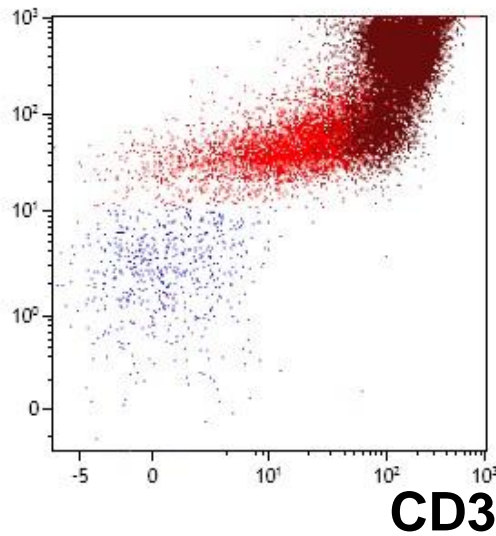
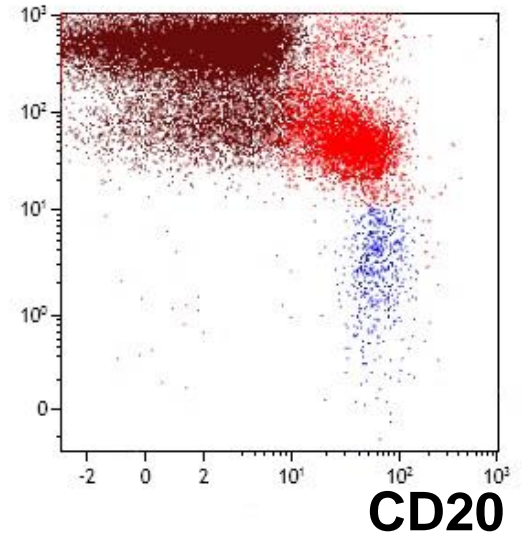
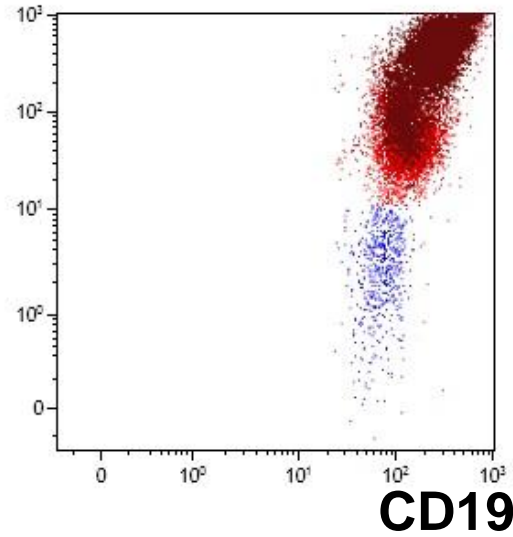
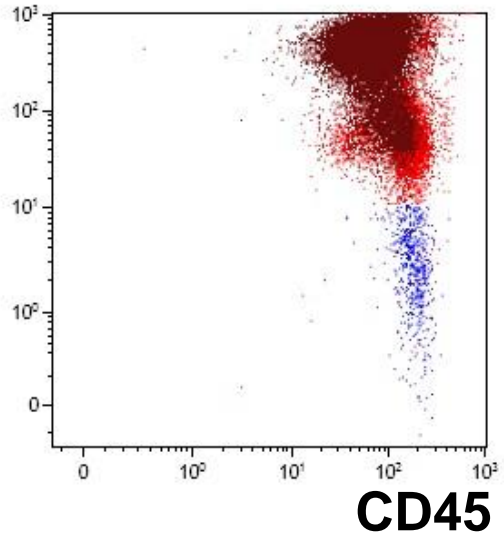
**CD34**



**CD20**

# Пациент П.

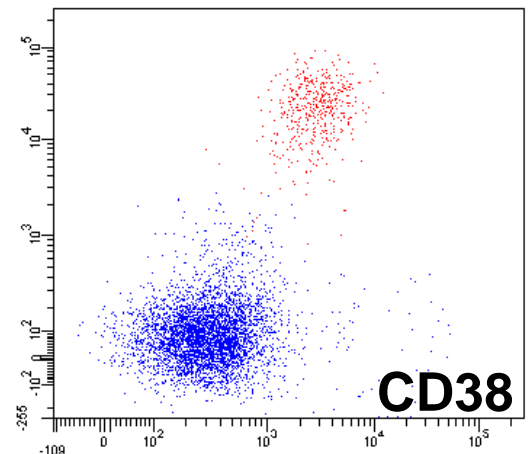
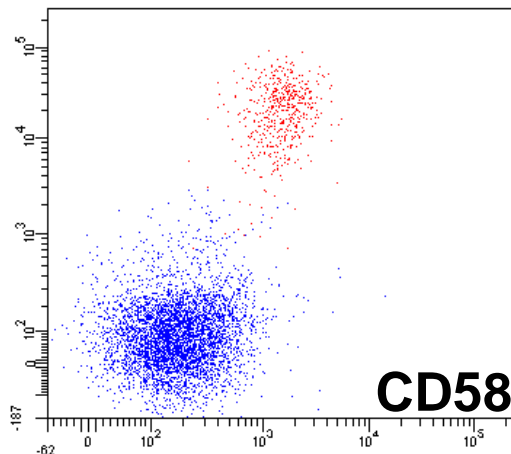
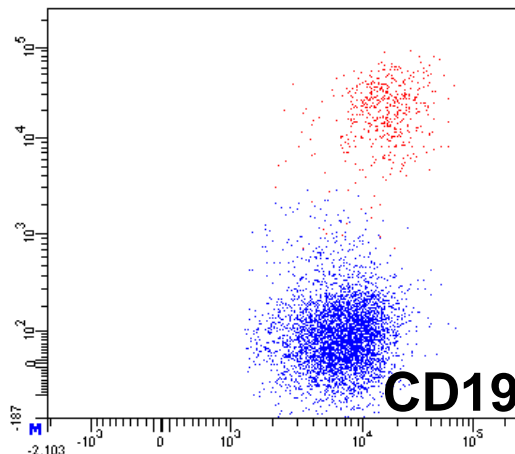
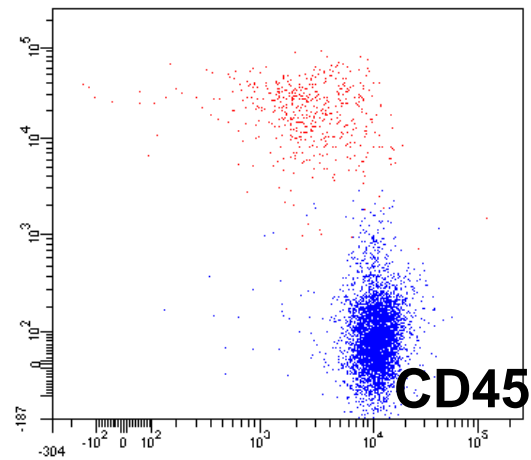
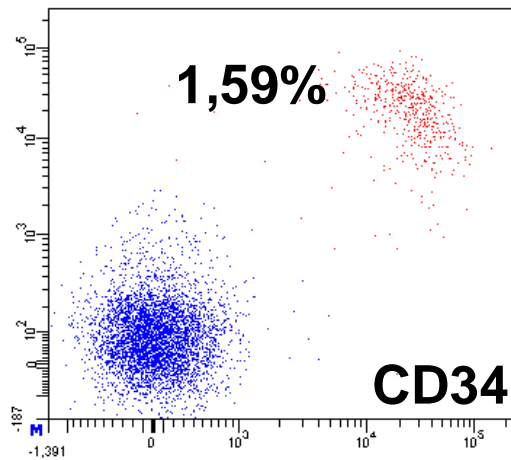
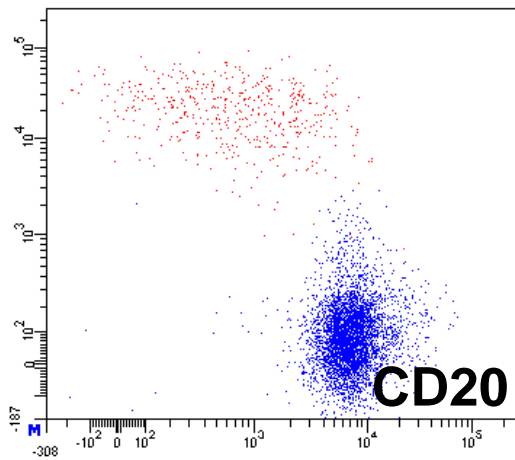
CD10



# **«Ранняя» диагностика ОЛЛ**

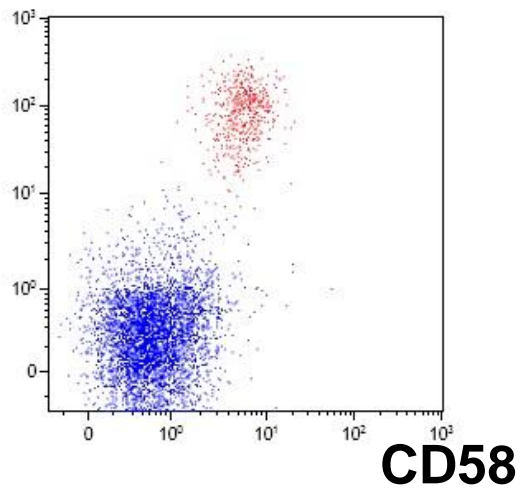
# Пациент С.

CD10

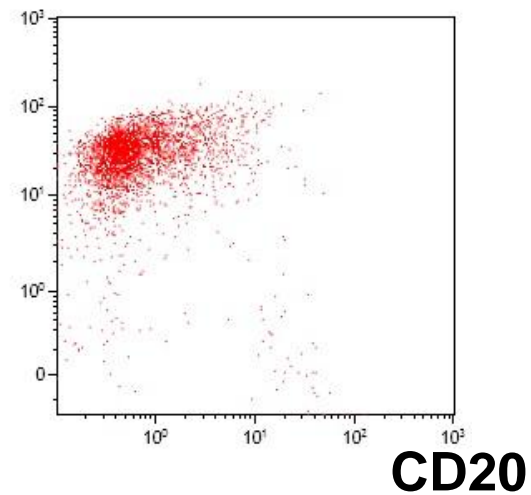
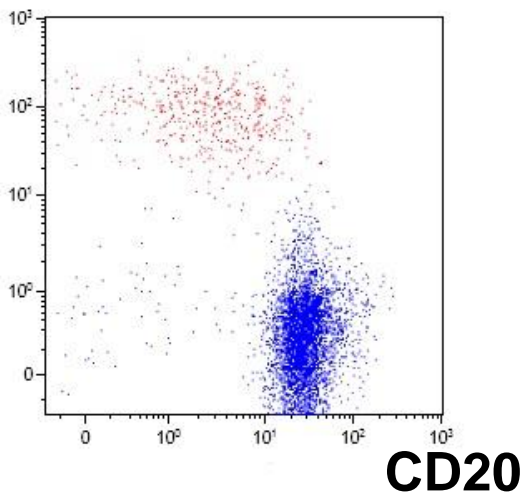
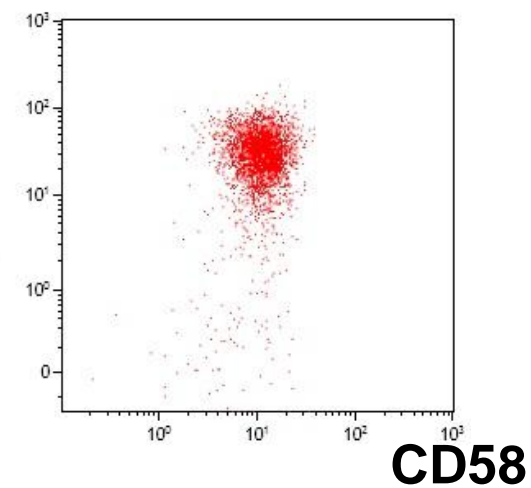


# Пациент С.

09.2014



01.2015\*



CD10


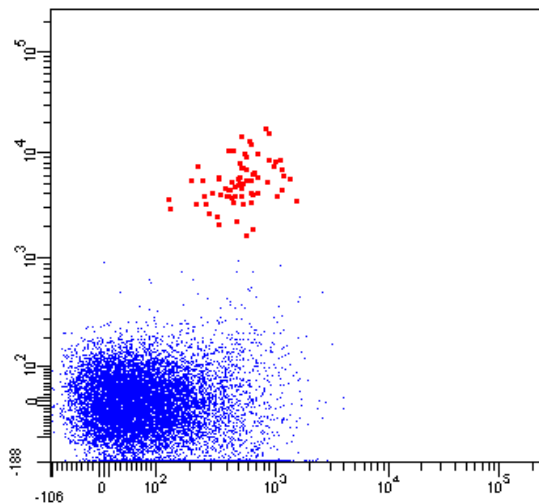

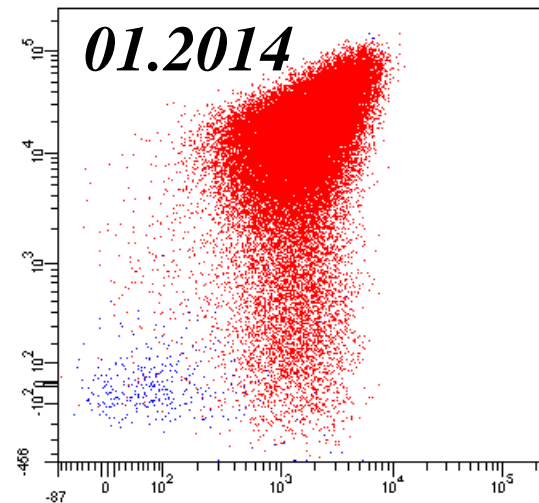
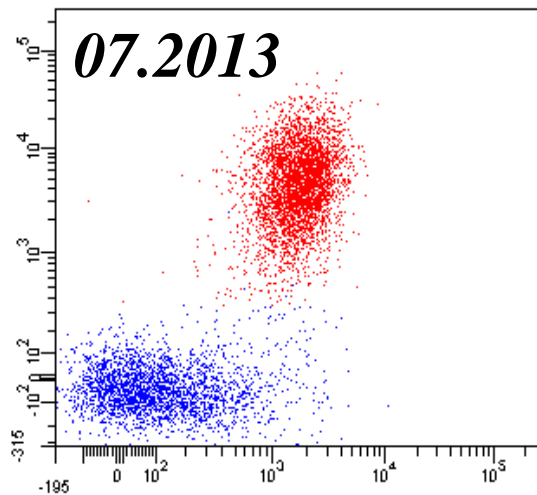
CD20

CD20

\*Данные предоставлены Л.В. Байдун

# Пациент Д.

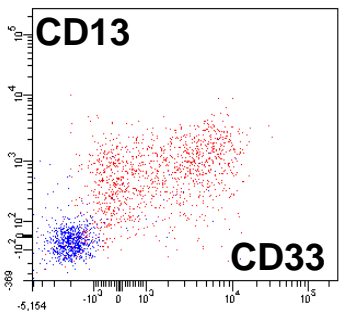
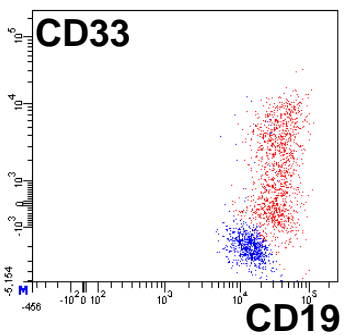
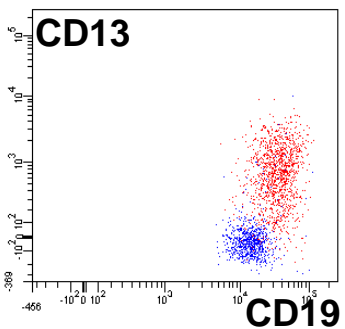
CD10



CD58

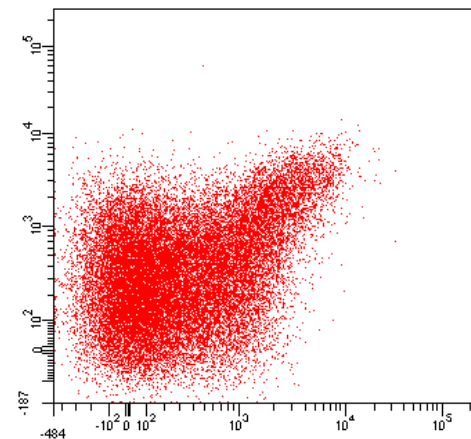
07.2013

# Пациент Д.



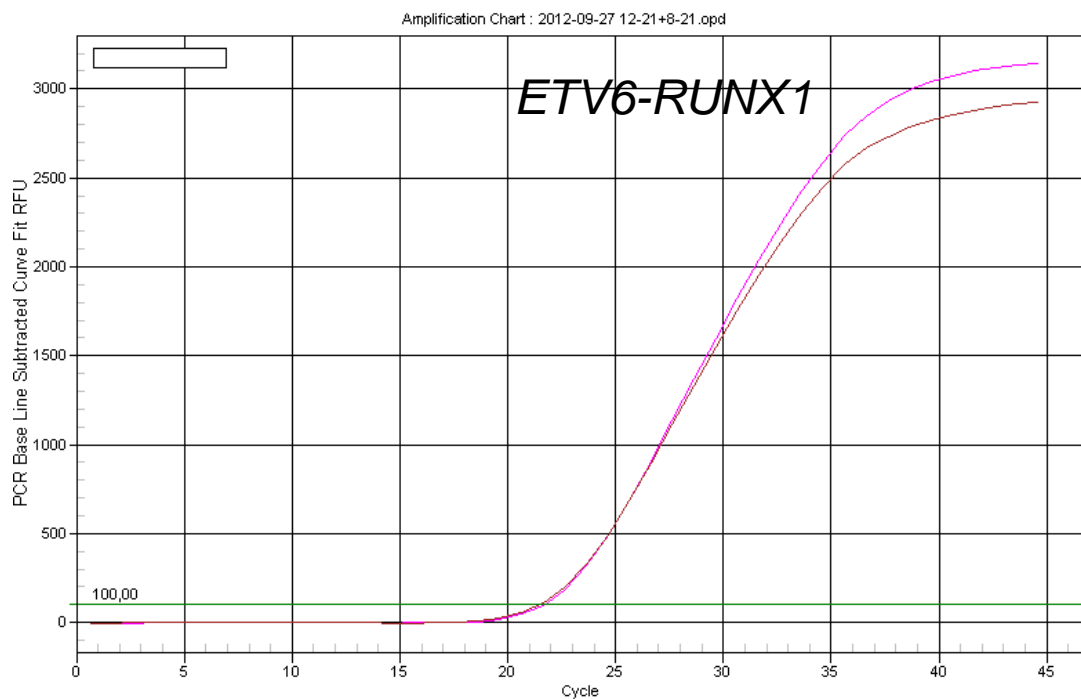
01.2014

CD13



CD33

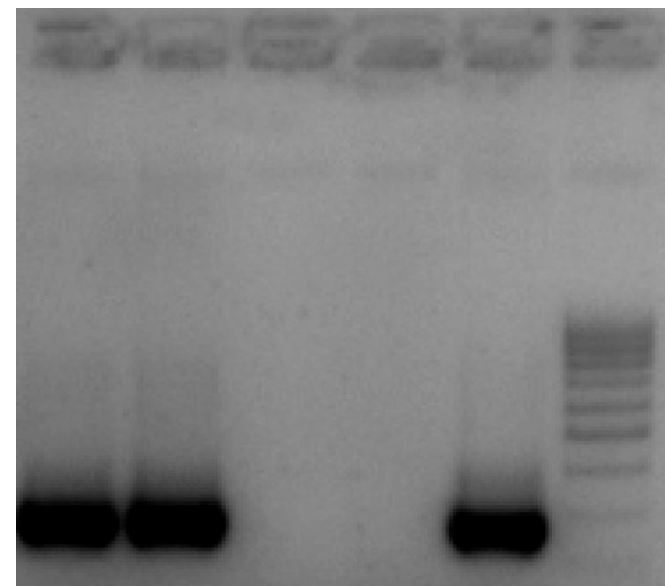
# Выявление химерного транскрипта *ETV6-RUNX1*



-7  
mec

DS

K+ M



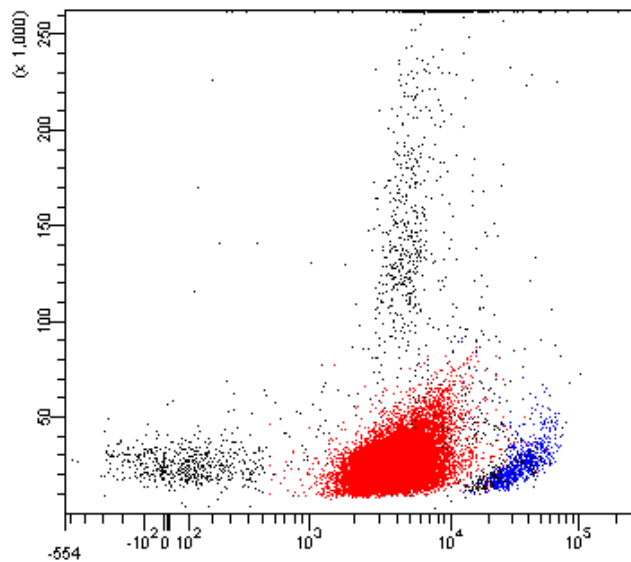


**«Случайная» диагностика рецидива ОЛ**

# Пациент Б.

*Диагноз*

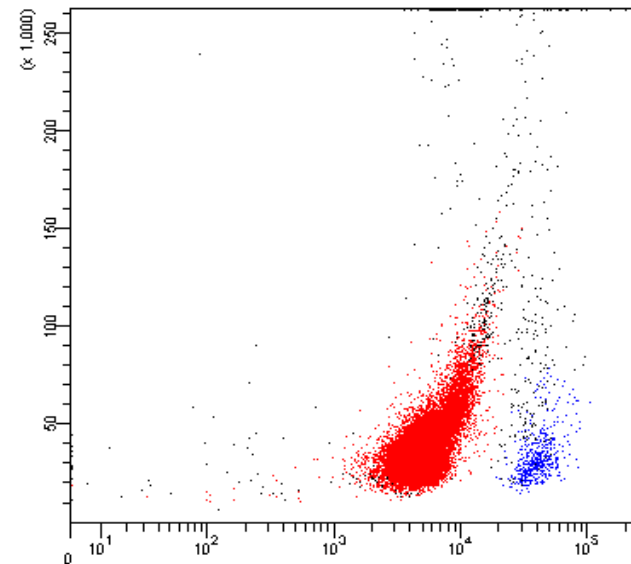
**SSC**



**CD45**

*Рецидив*

**SSC**

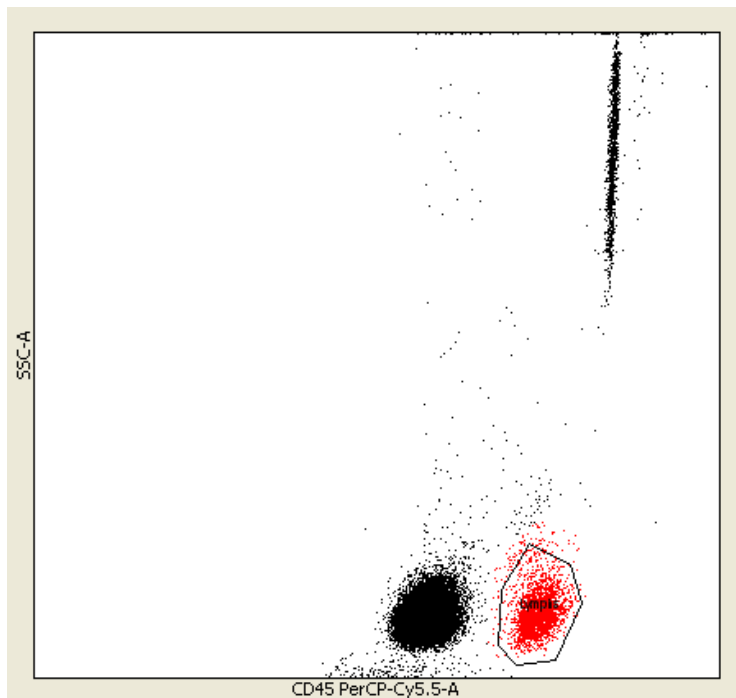


**CD45**



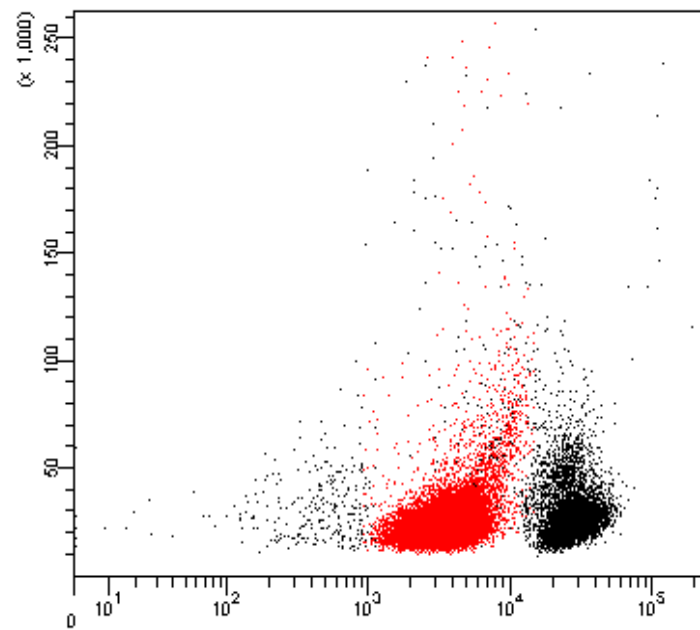
# Пациент Б. (периферическая кровь)

SSC



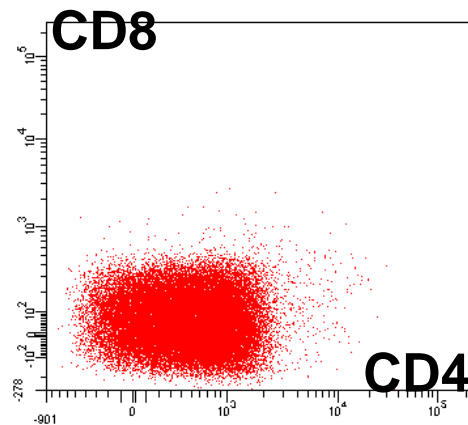
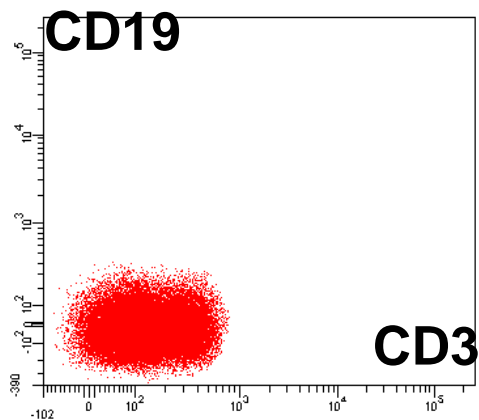
CD45

SSC

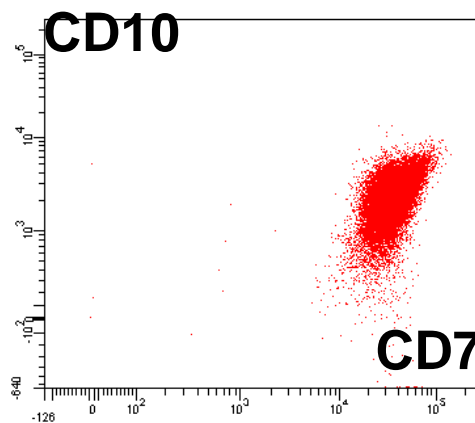
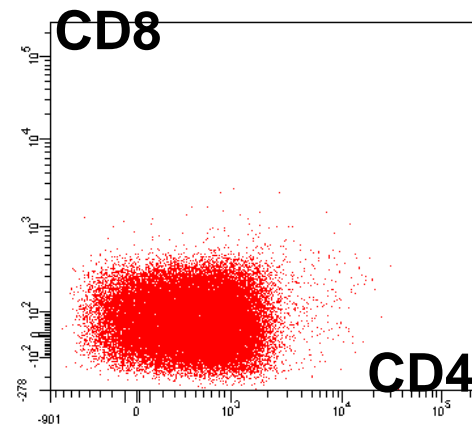
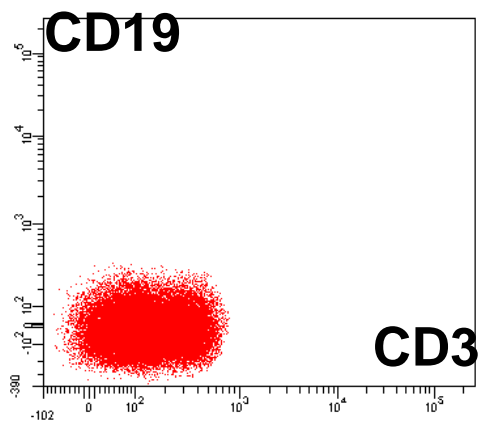


CD45

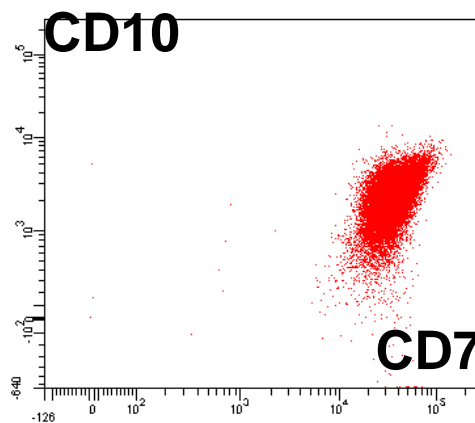
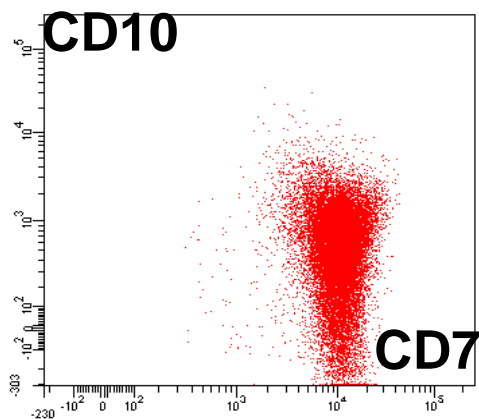
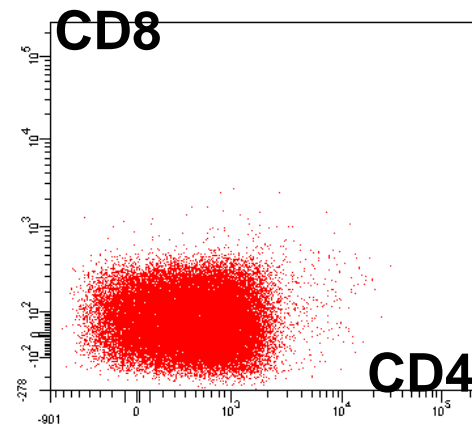
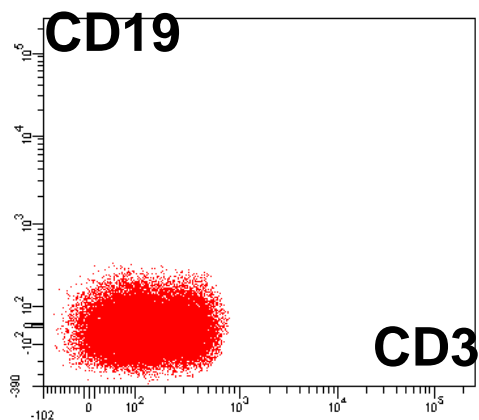
# Пациент Б. (периферическая кровь)



# Пациент Б. (периферическая кровь)

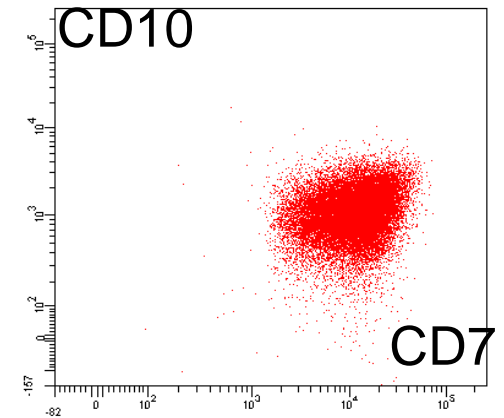
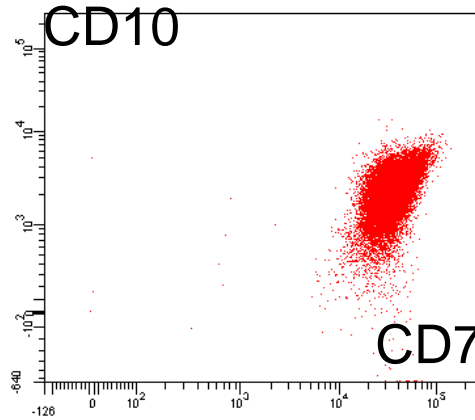
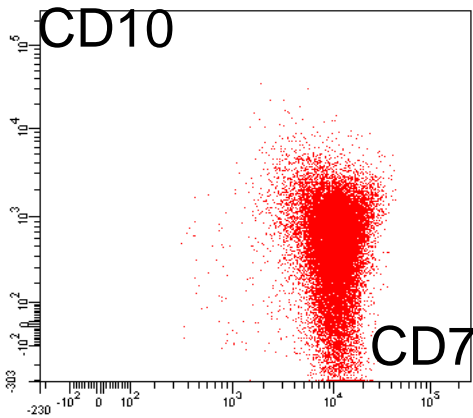
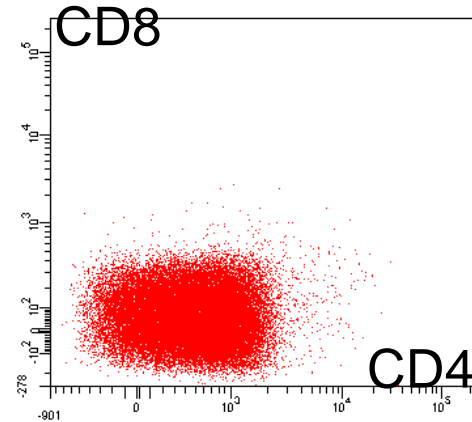
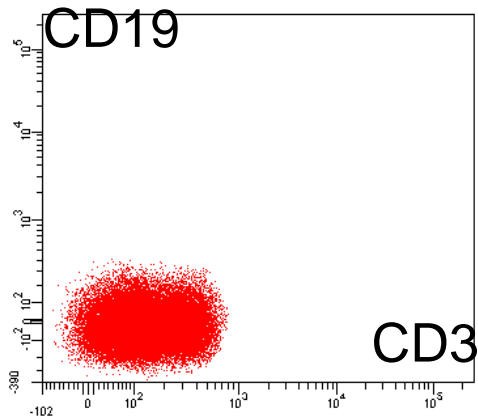


# Пациент Б. (периферическая кровь)



*Костный мозг*  
*Диагноз*

# Пациент Б. (периферическая кровь)



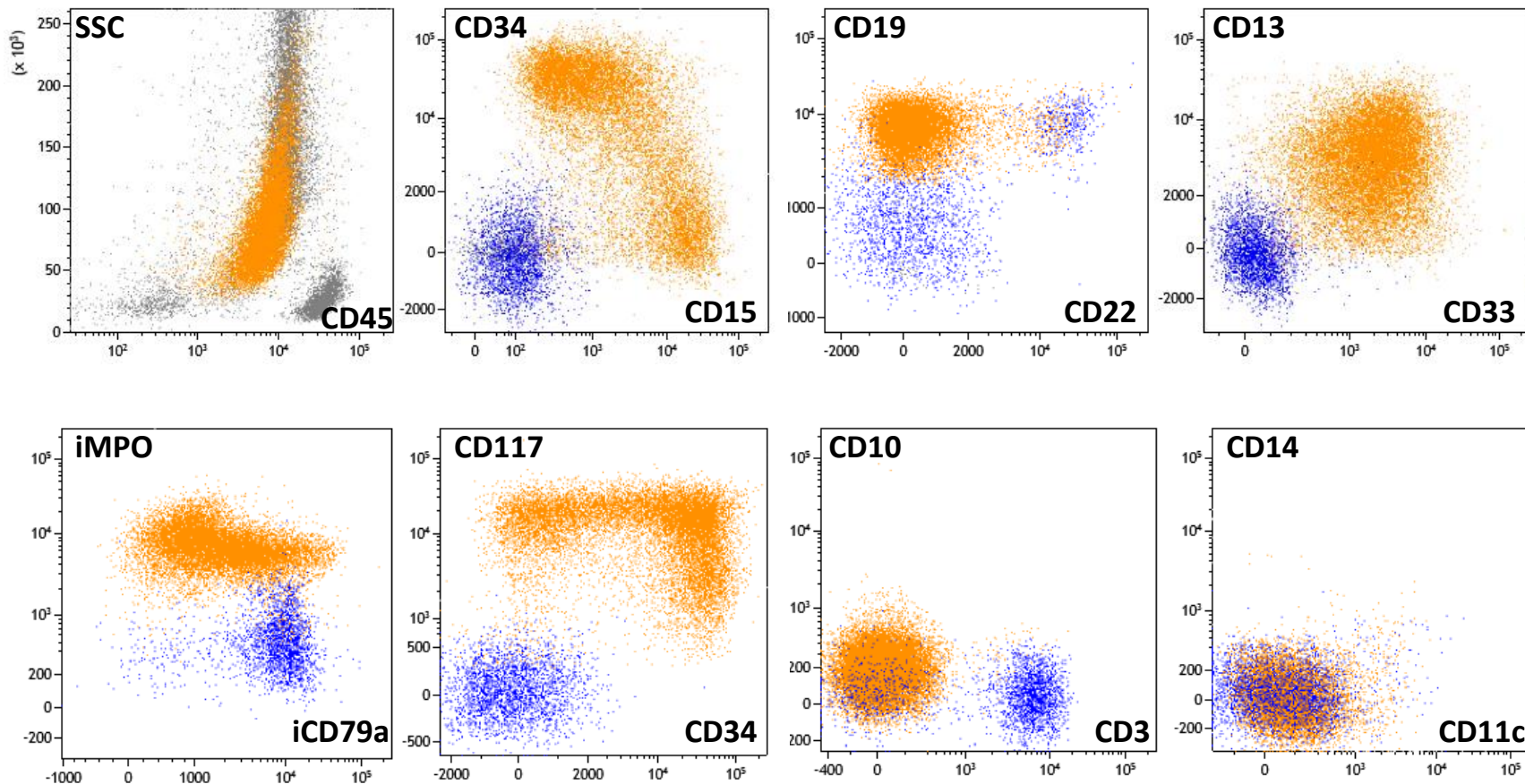
*Костный мозг  
Диагноз*

*Костный мозг  
Рецидив*

# **Диагностика МРАЛ**

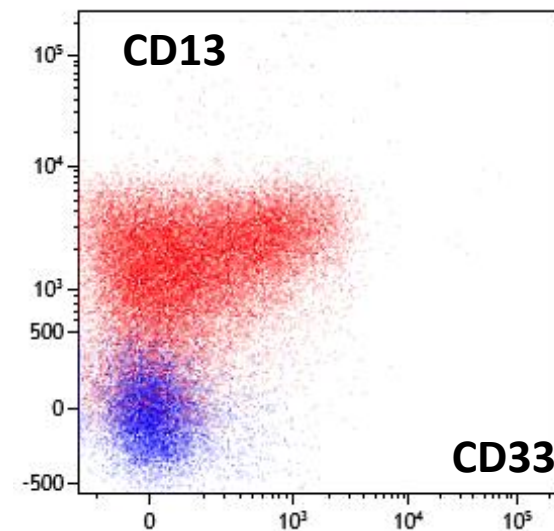
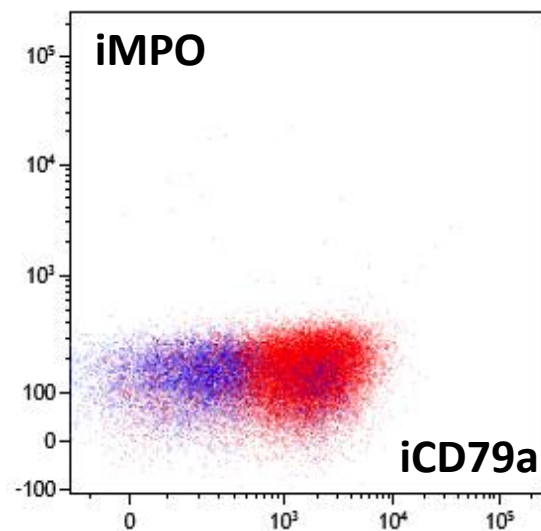
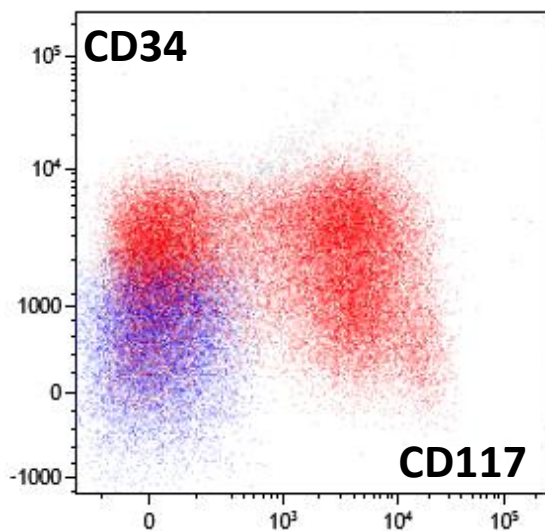
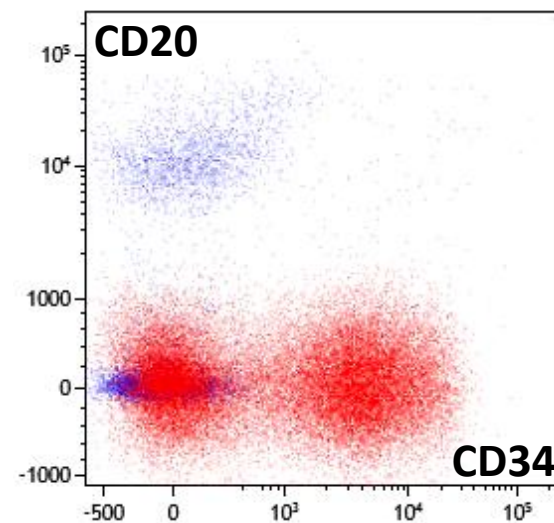
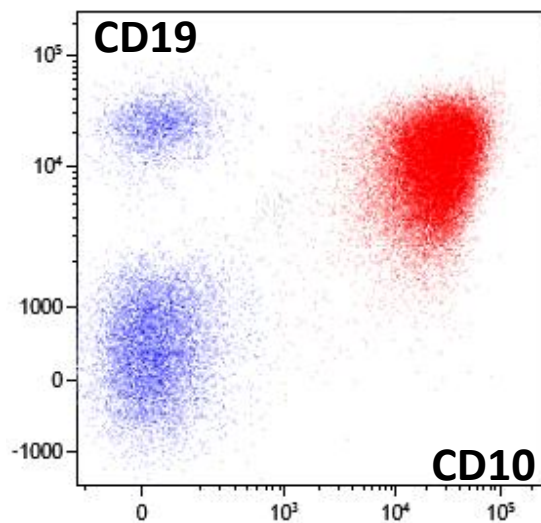
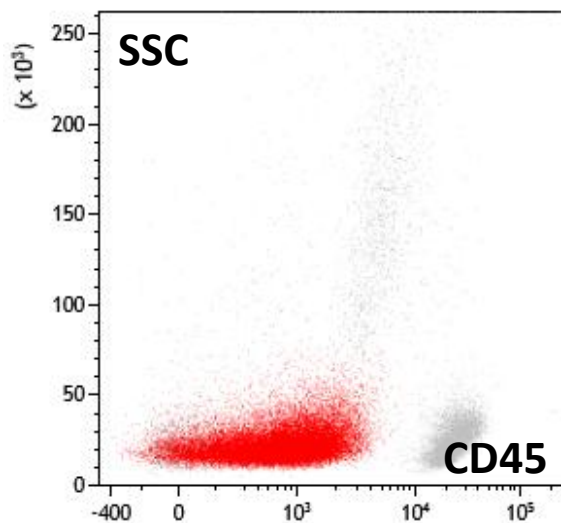


# Острый бифенотипический лейкоз???



*OML c RUNX1-RUNX1T1*

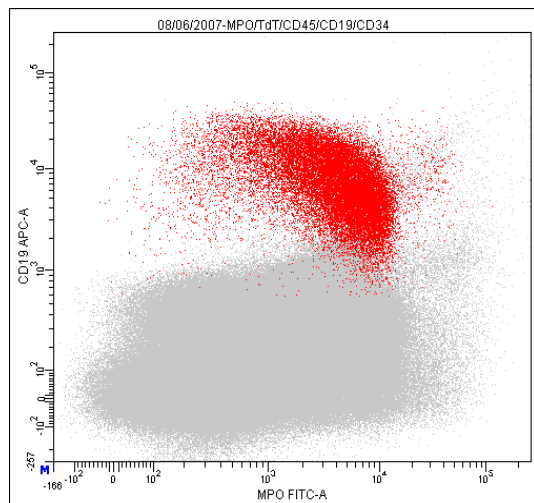
# Острый бифенотипический лейкоз???



*ОЛЛ с ETV6-RUNX1*

# «Странные» фенотипы, возникающие под действием терапии

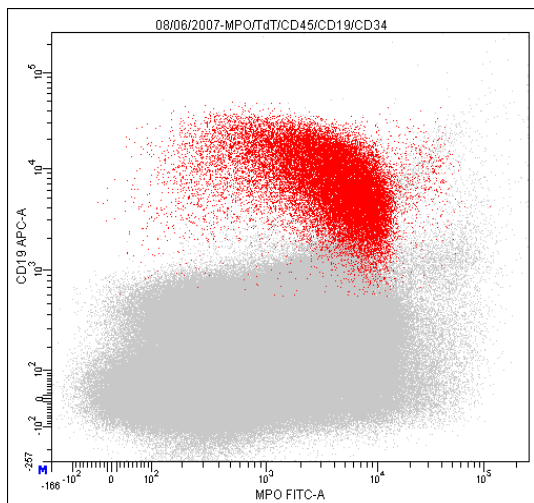
**CD19**



**MPO**

# «Странные» фенотипы, возникающие под действием терапии

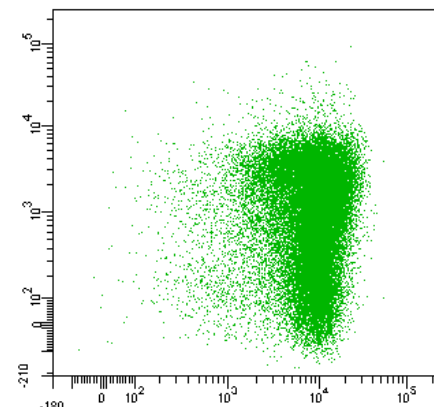
**MPO**



**CD19**

**FACS Perm 2**

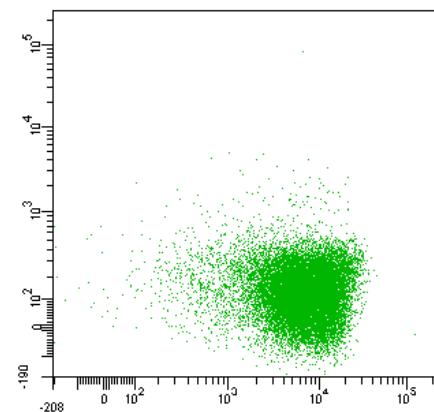
**MPO**



**CD19**

**MPO**

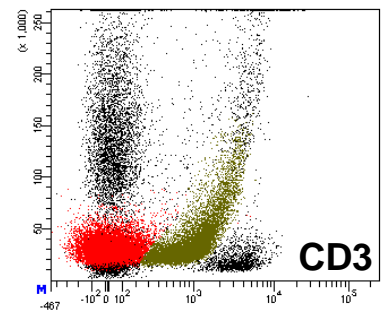
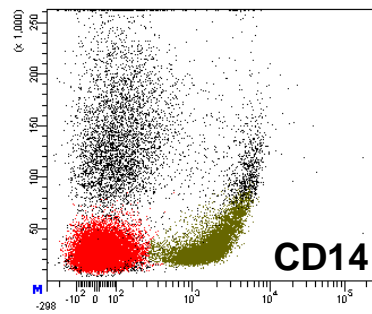
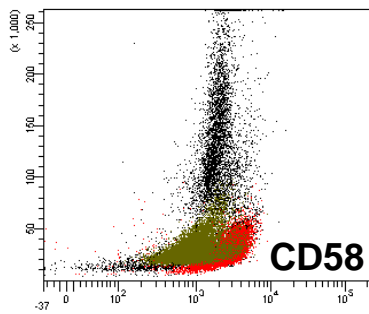
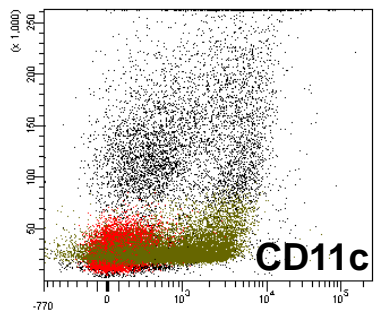
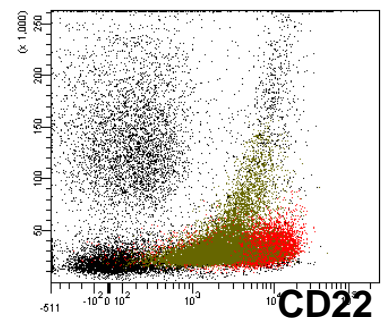
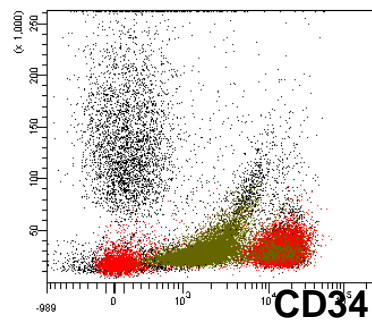
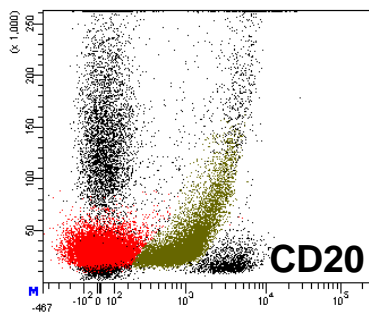
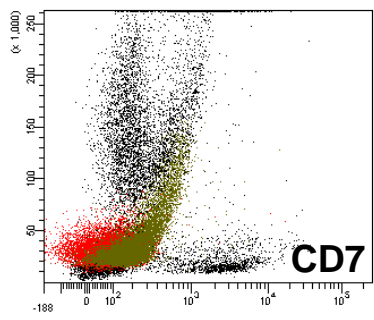
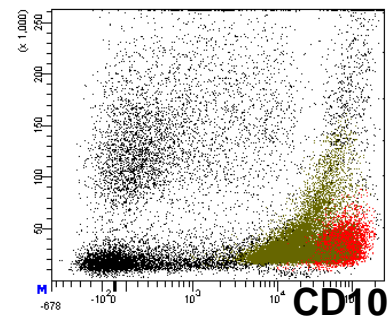
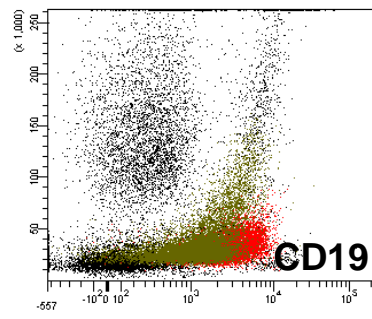
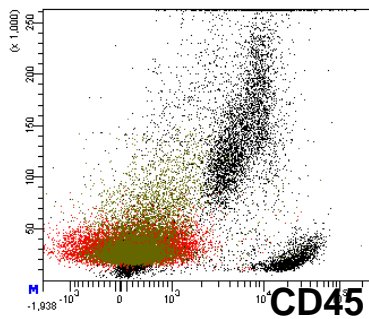
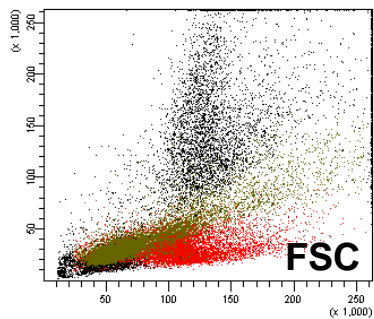
**Fix&Perm**



**CD19**

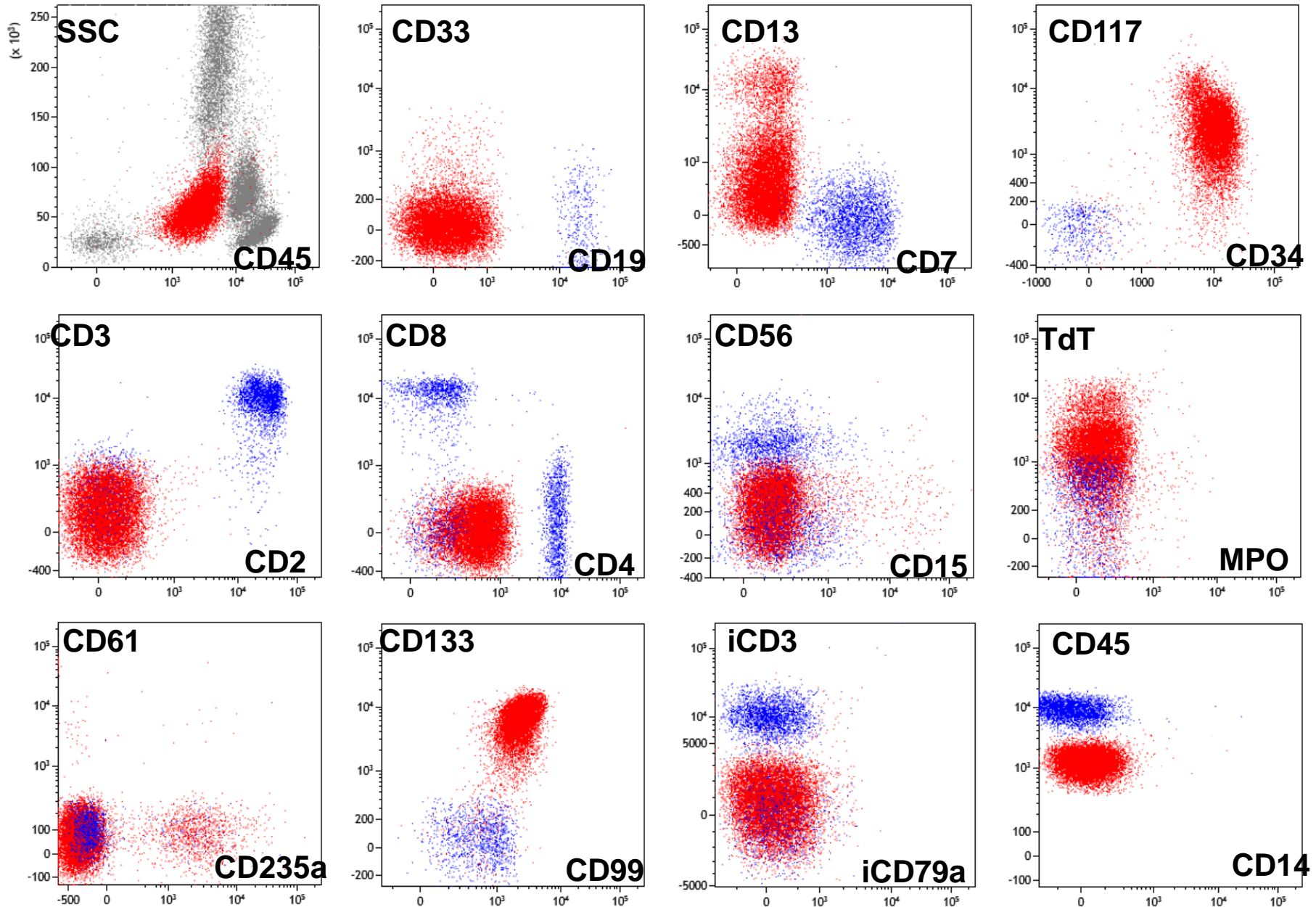
# Пациент К.

SSC



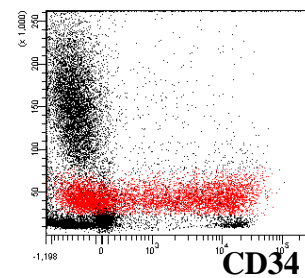
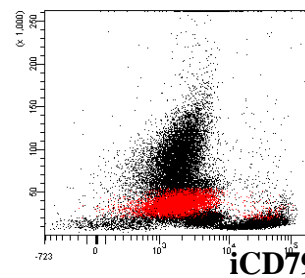
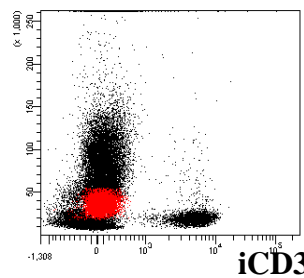
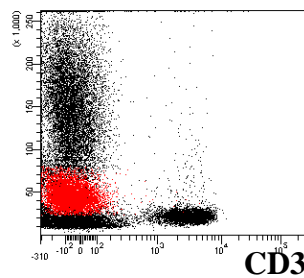
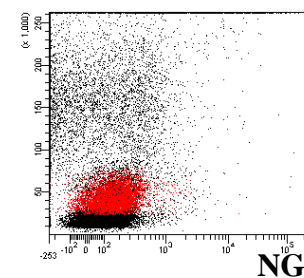
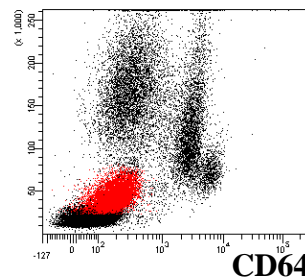
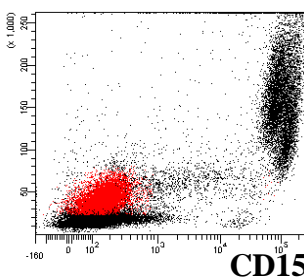
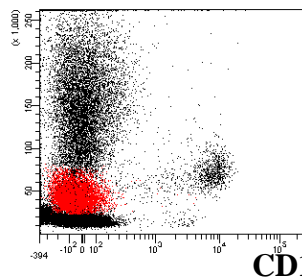
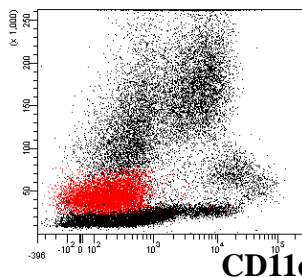
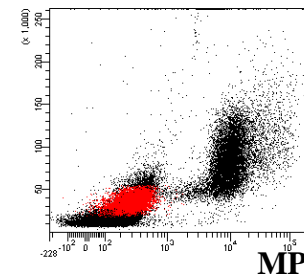
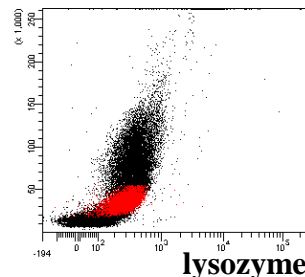
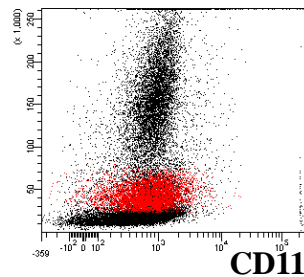
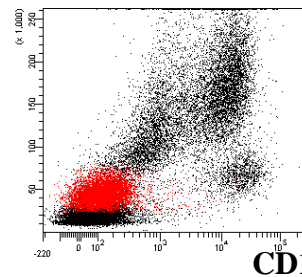
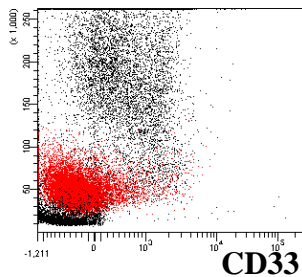
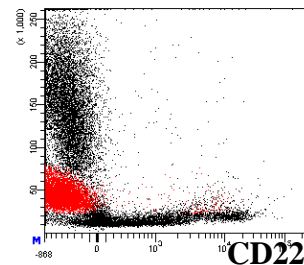
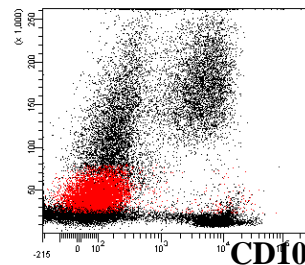
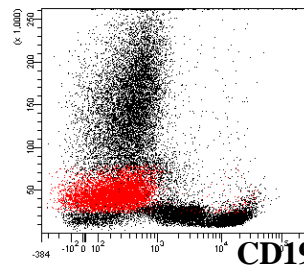
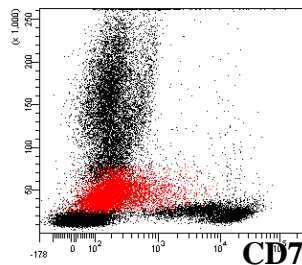
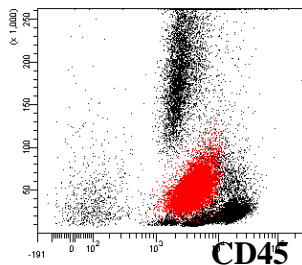
# **Диагностика острого недифференцированного лейкоза**

# Острый недифференцированный лейкоз



# Пациент С.

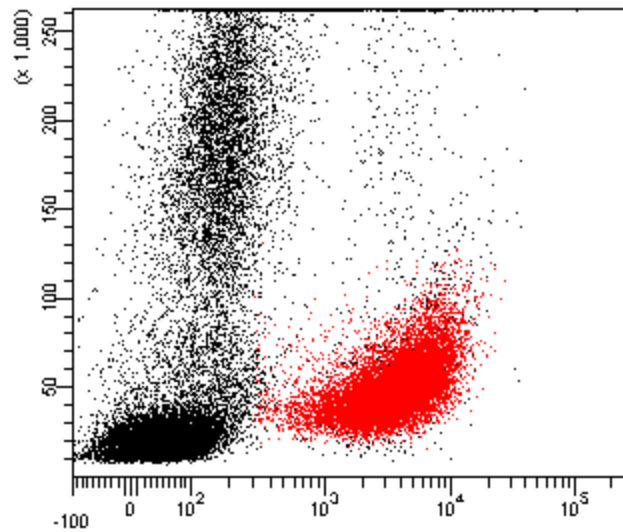
SSC





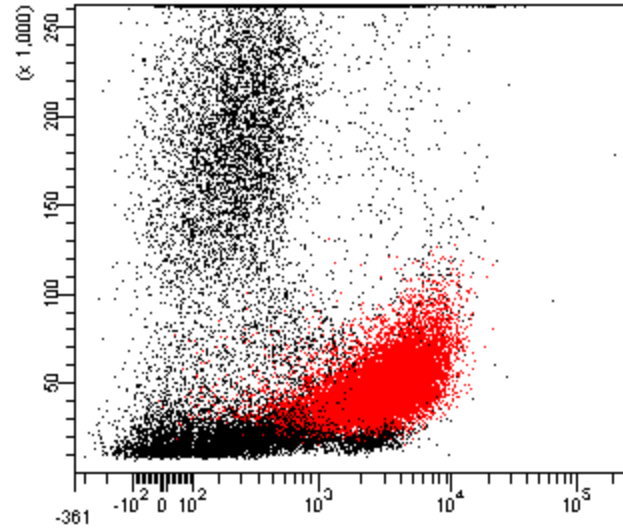
# Пациент С.

**SSC**



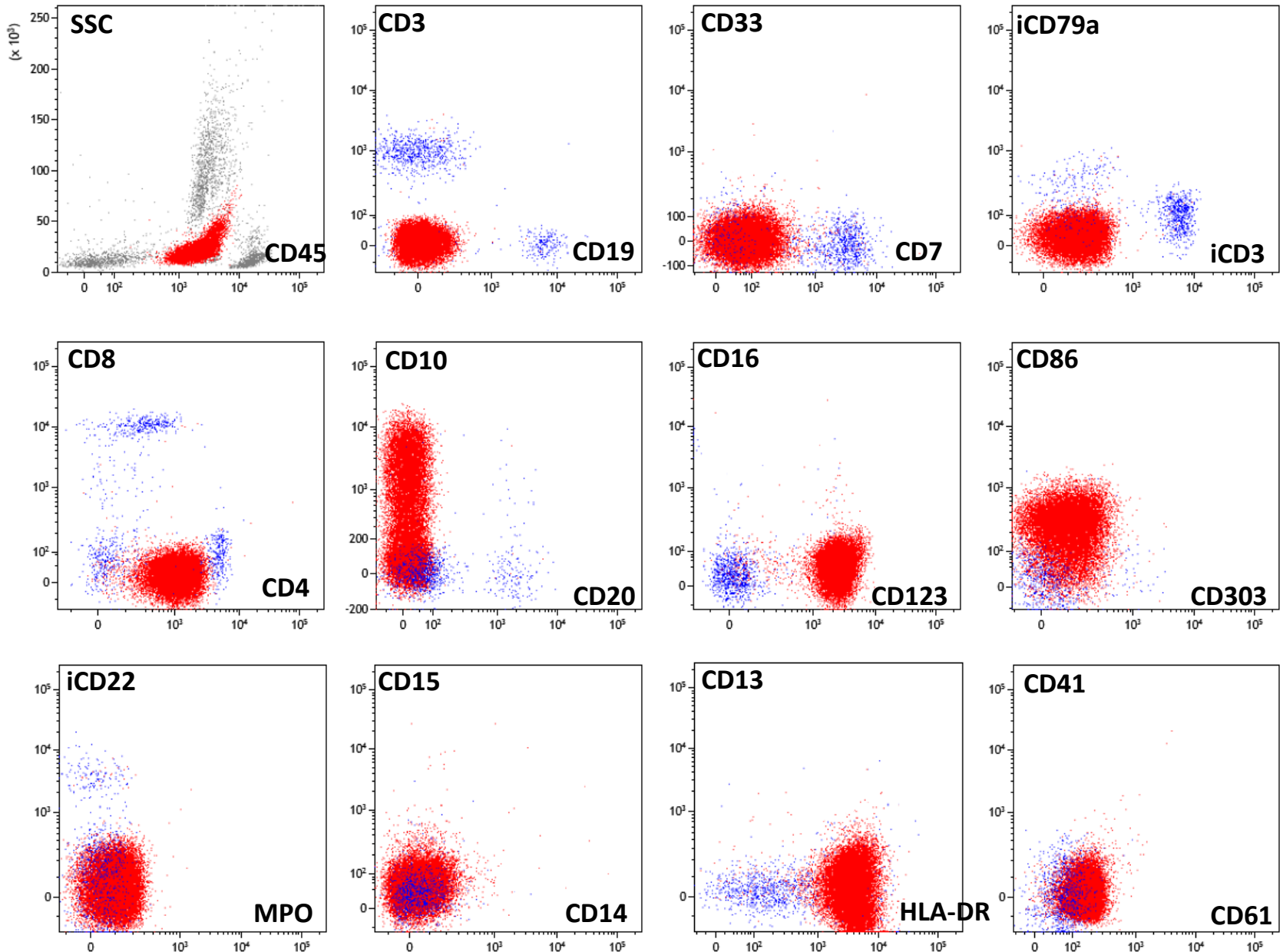
**CD61**

**SSC**



**CD41a**

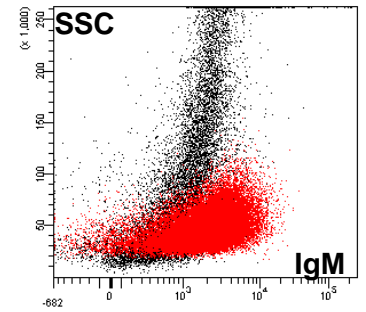
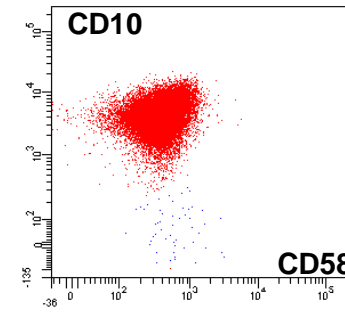
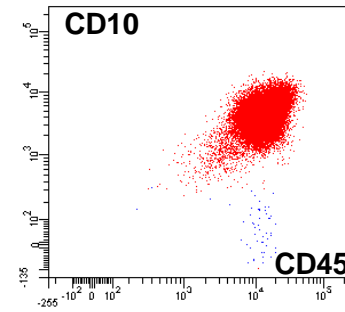
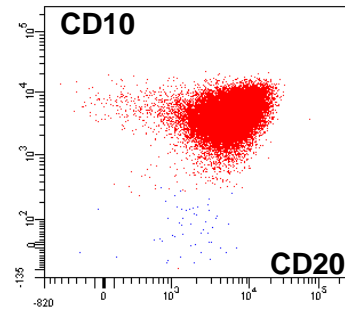
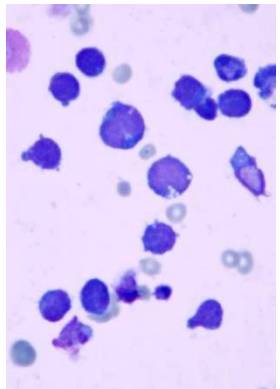
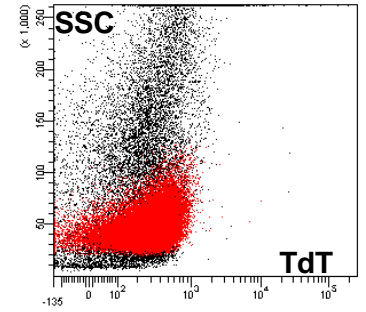
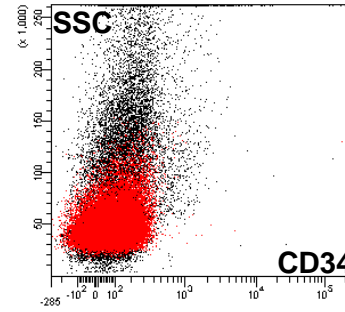
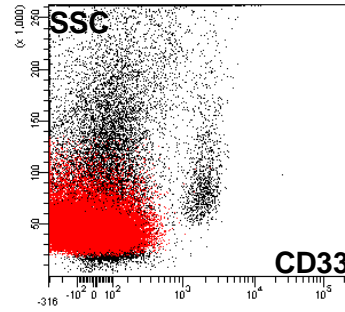
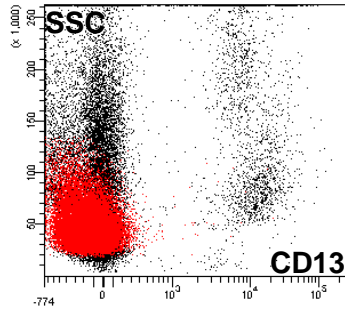
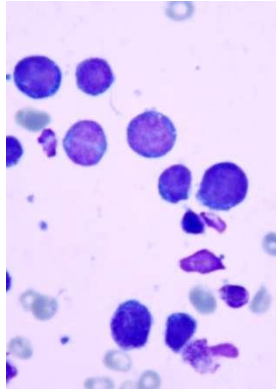
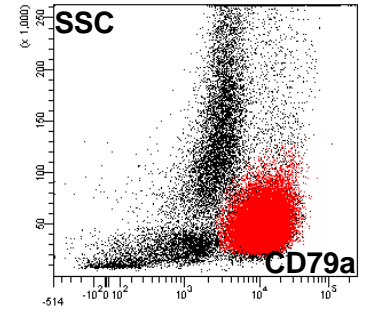
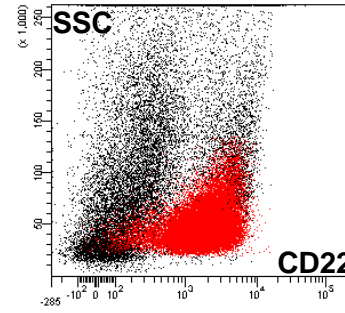
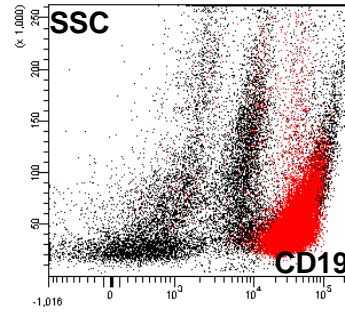
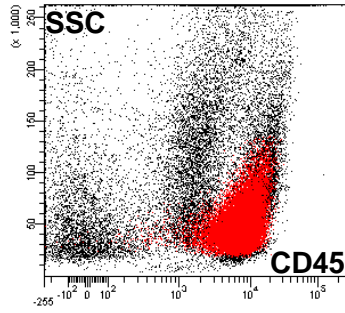
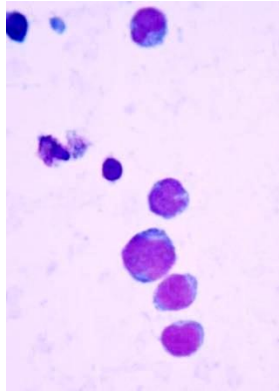
# Острый лейкоз из дендритных клеток



# **Исследуемый материал**

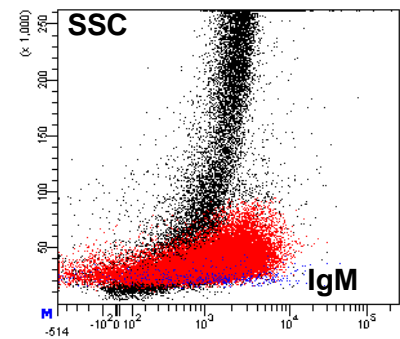
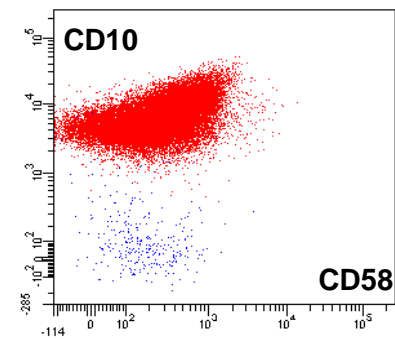
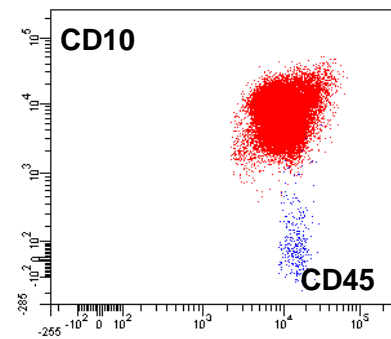
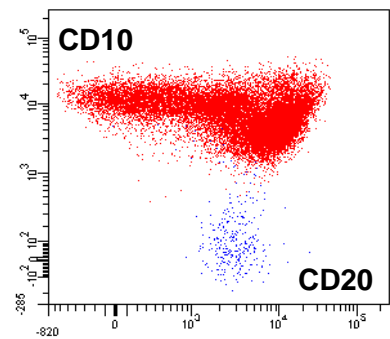
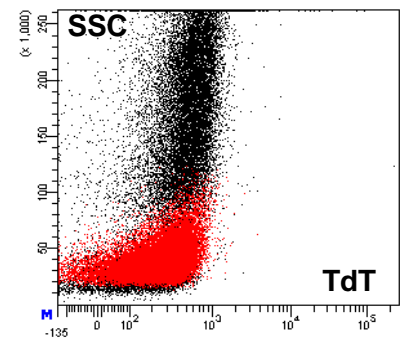
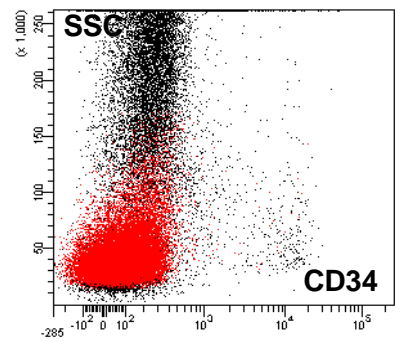
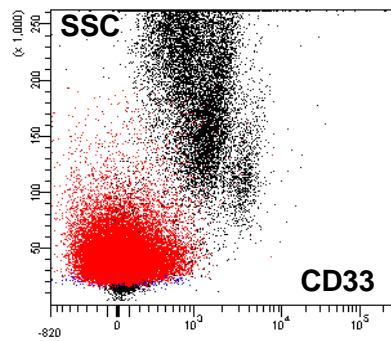
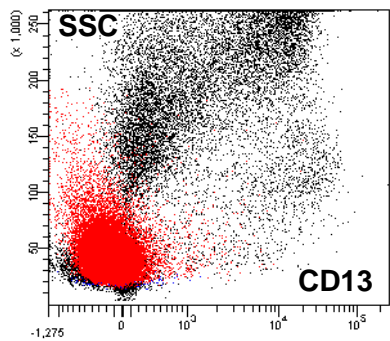
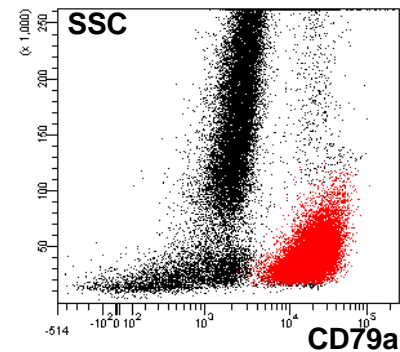
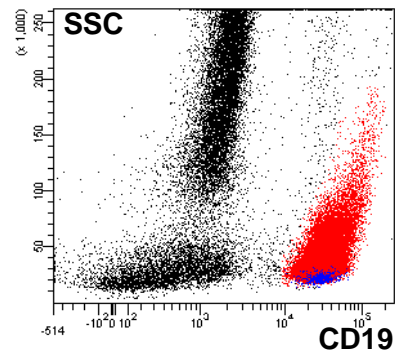
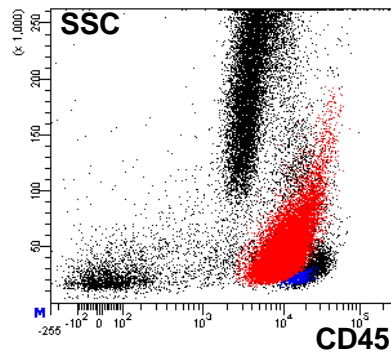
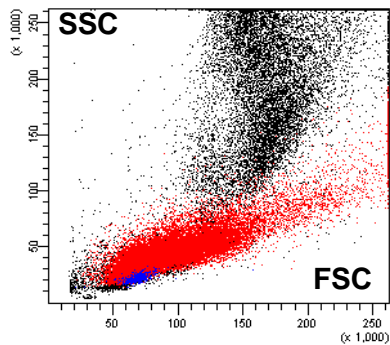
# Пациент П.

## *плевральный выпот*



# Пациент П.

## *КОСТНЫЙ МОЗГ*

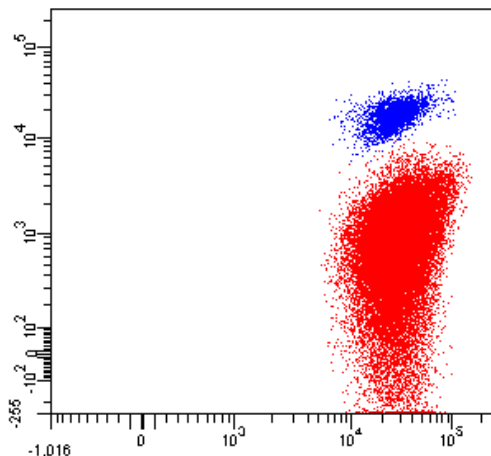


# Выявление опухолевых клеток в СМЖ при В-линейном ОЛЛ

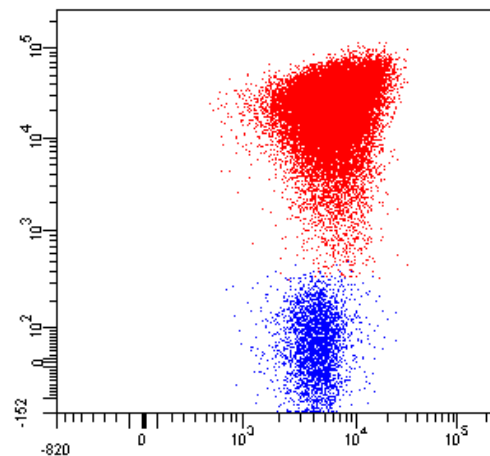
Пациент Г.

**КМ**

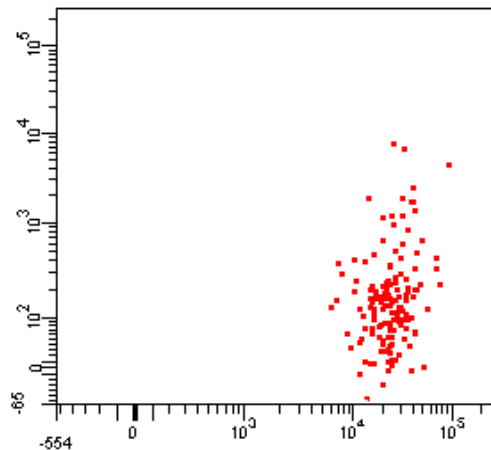
**CD45**



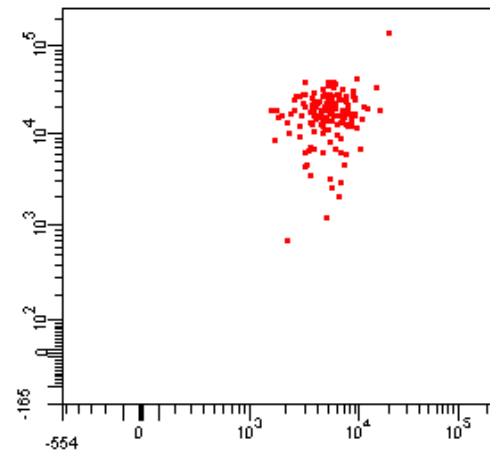
**CD34**



**СМЖ**



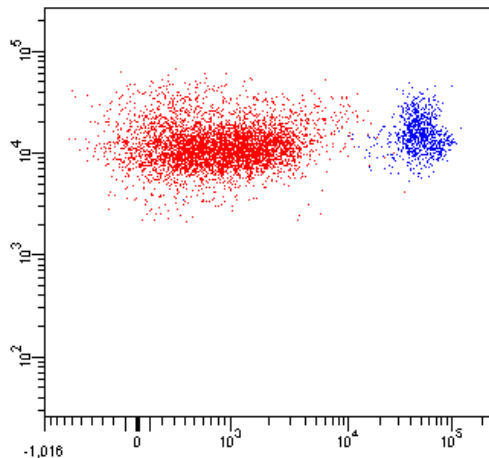
**CD19**



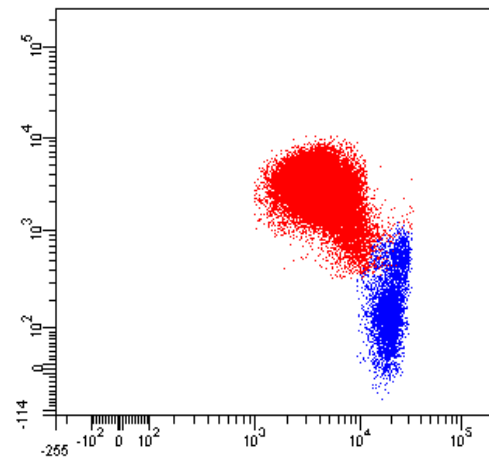
# Выявление опухолевых клеток в СМЖ при Т-ОЛЛ

**КМ**

**Пациент М.**

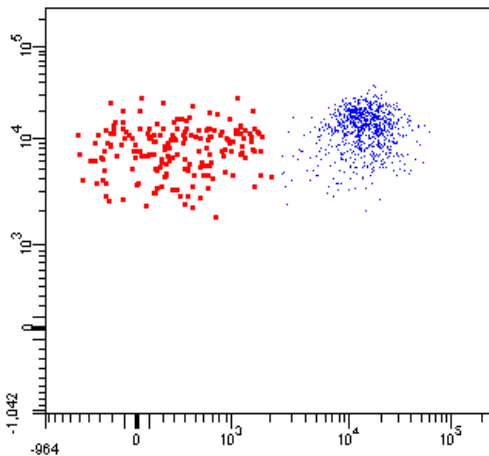


**Пациент С.**

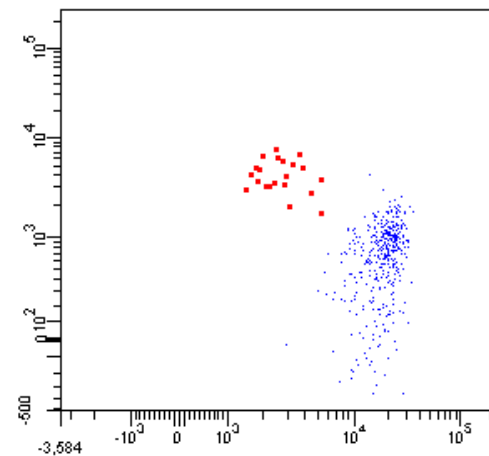


**СМЖ**

**CD2**



**CD99**



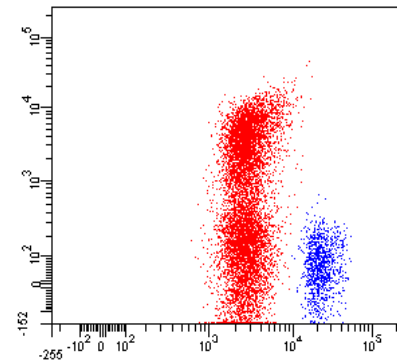
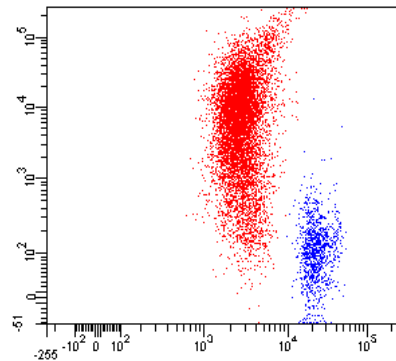
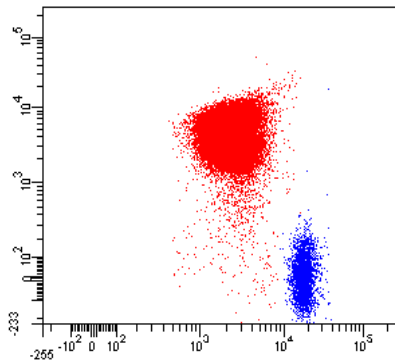
**CD3**

**CD45**

# Выявление опухолевых клеток в СМЖ при ОМЛ

Пациент Д.

КМ

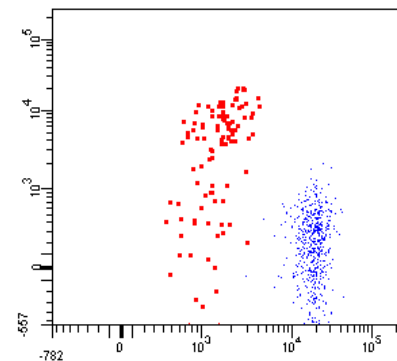
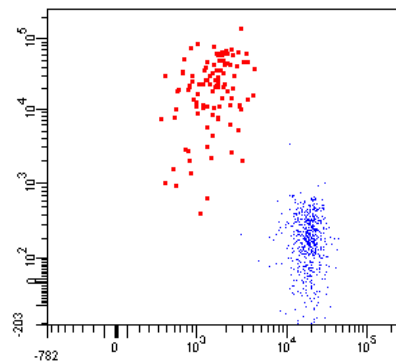
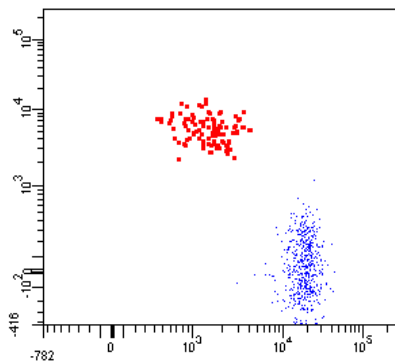


CD33

CD65

NG2

СМЖ



CD45



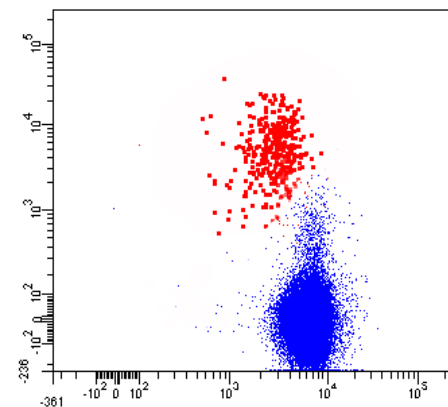
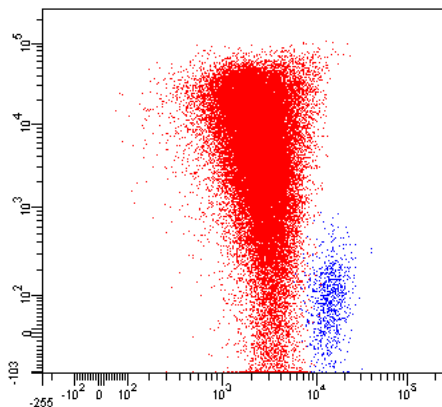
# Мониторинг поражения ЦНС у пациента с ВИ-ОЛЛ

**КМ**

**День 0**



**День 15**



**CD10**

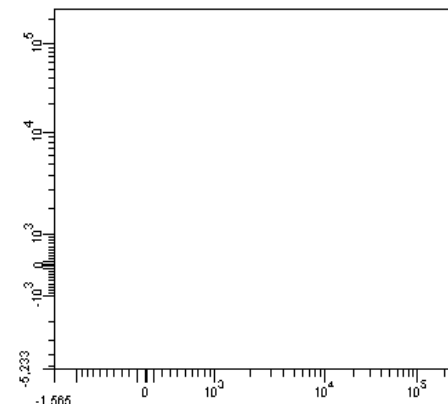
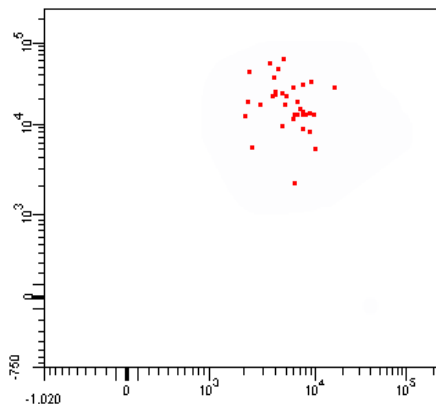
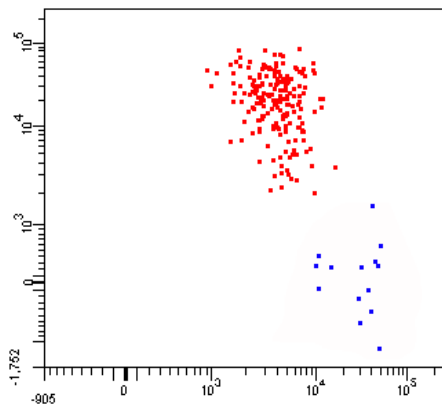
**День 0**



**День 8**



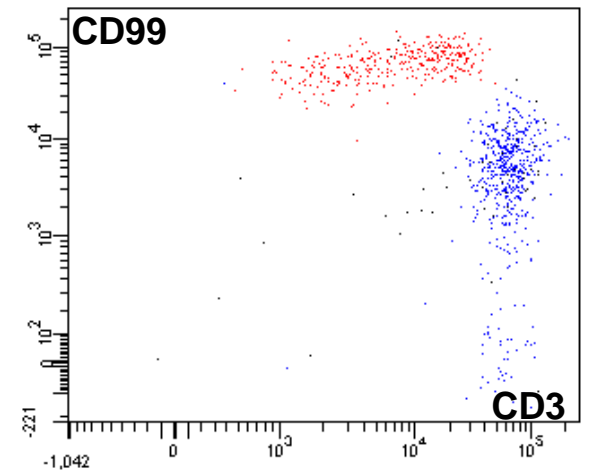
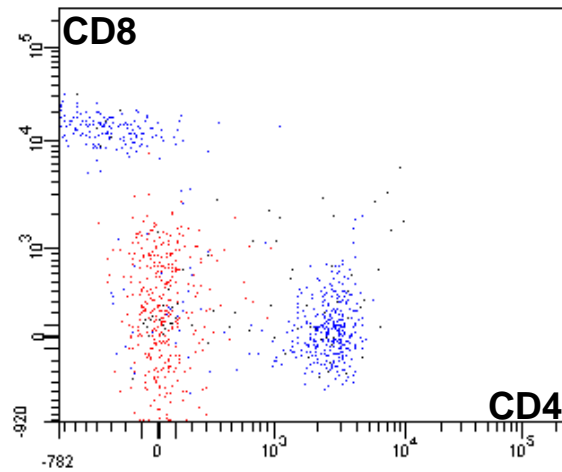
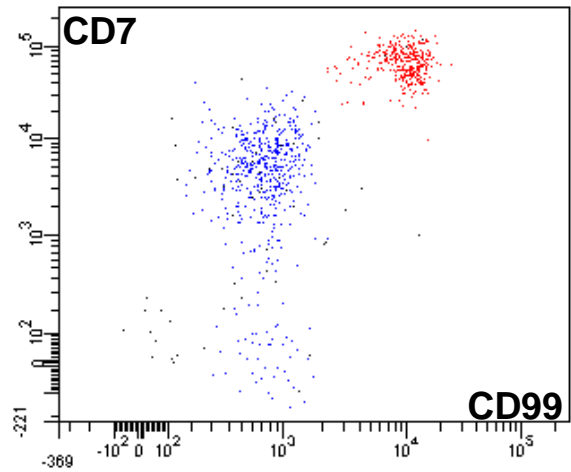
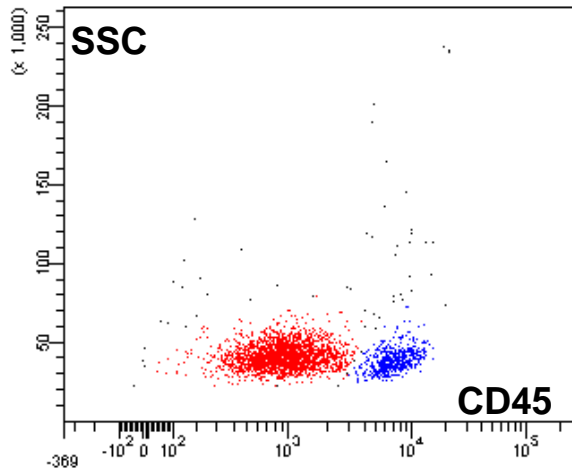
**День 15**



**СМЖ**

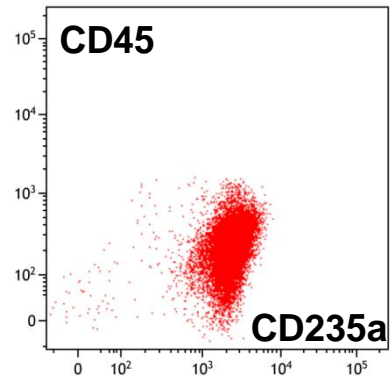
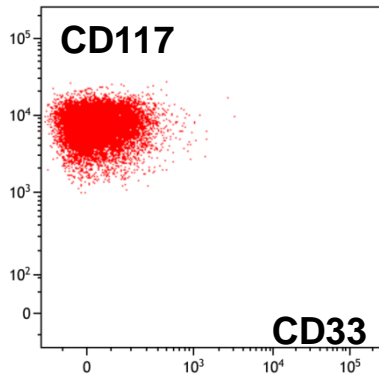
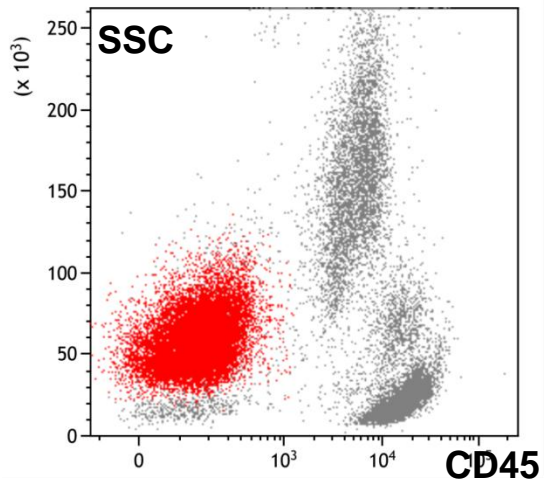
**CD45**

# Пациент Б. (спинномозговая жидкость)



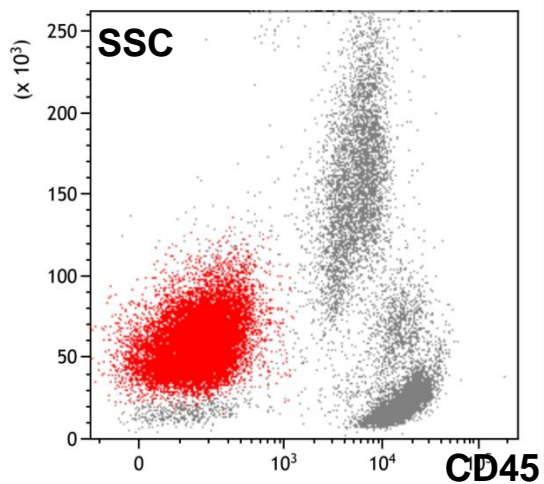
# Пациент С.

## КОСТНЫЙ МОЗГ

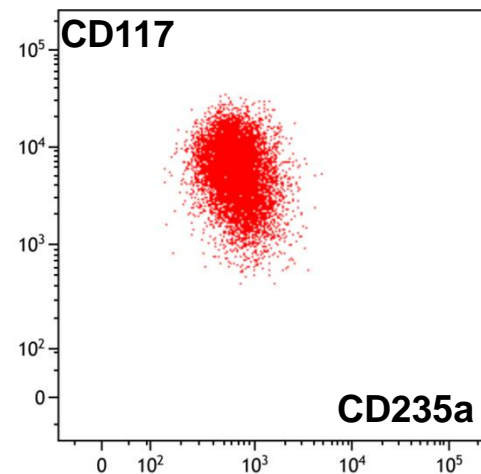
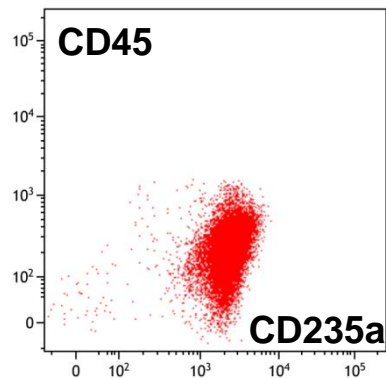
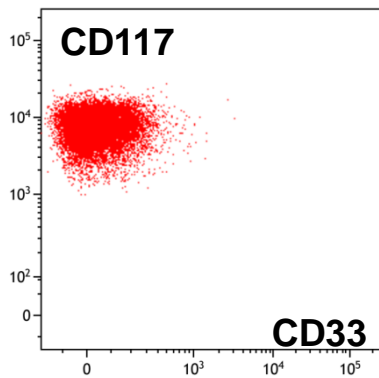
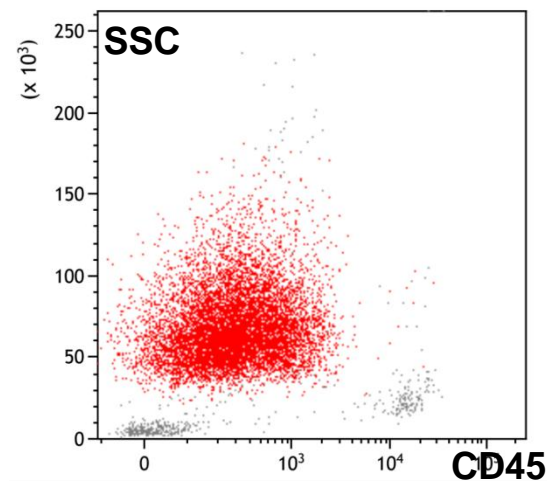


# Пациент С.

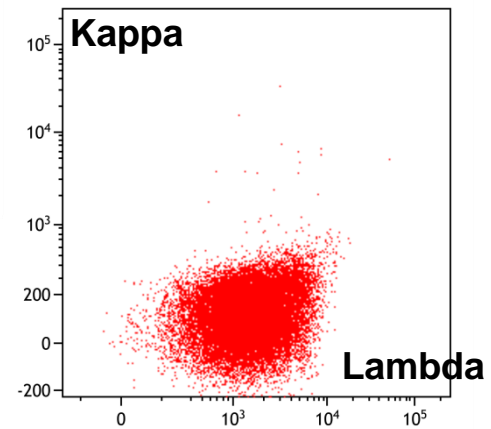
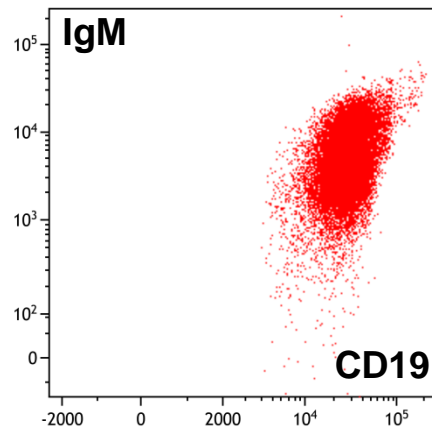
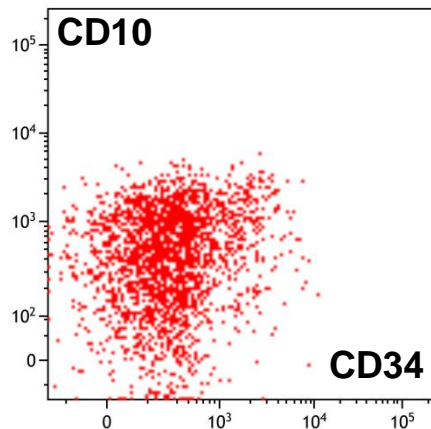
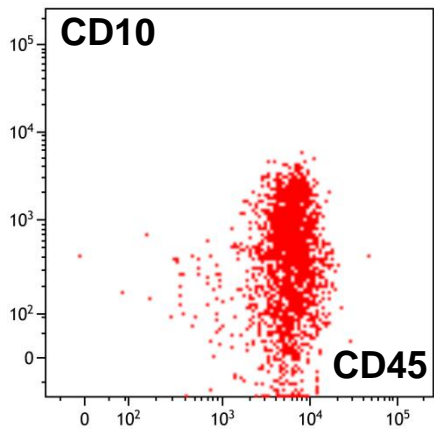
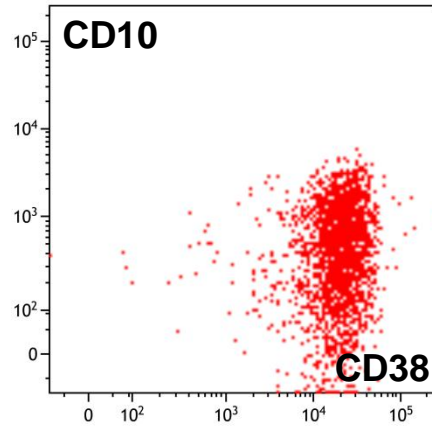
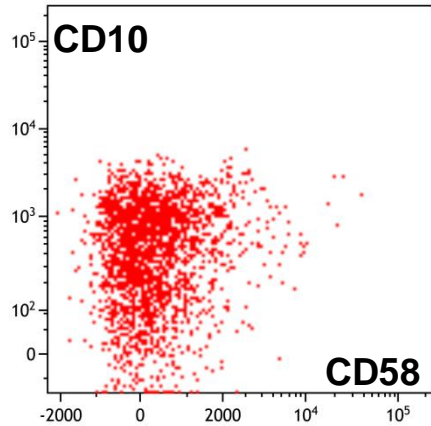
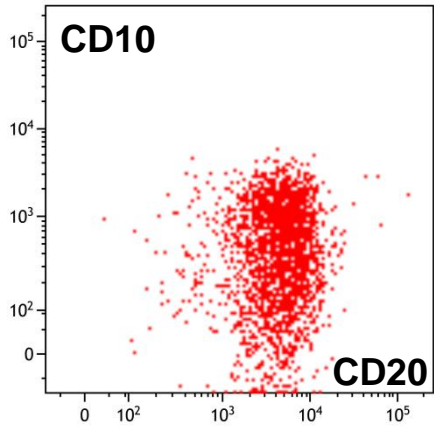
Костный мозг



Спинномозговая жидкость

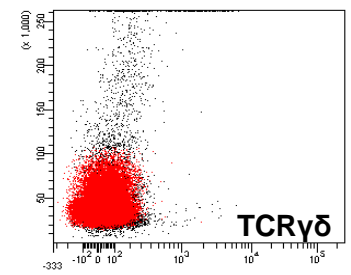
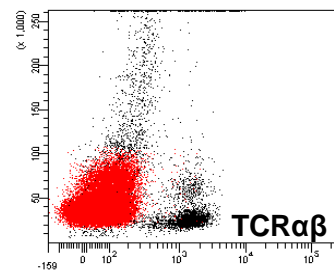
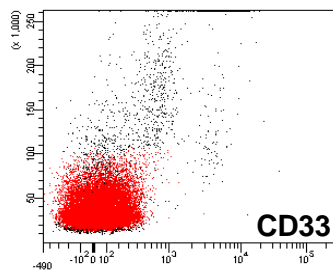
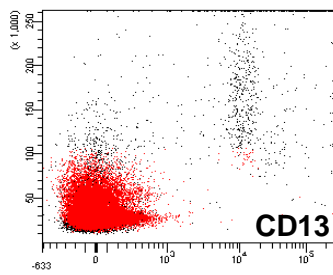
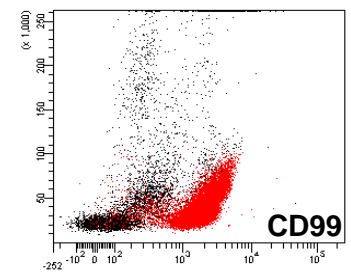
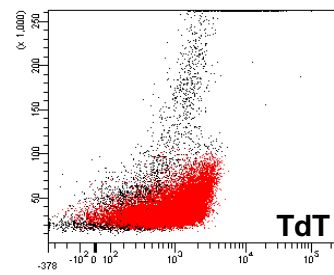
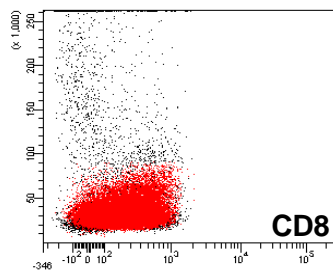
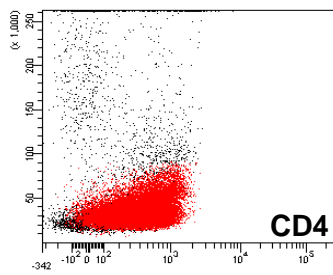
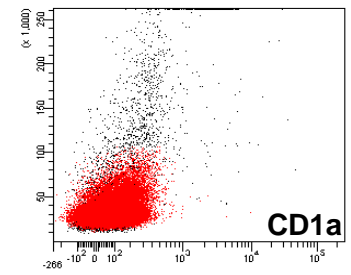
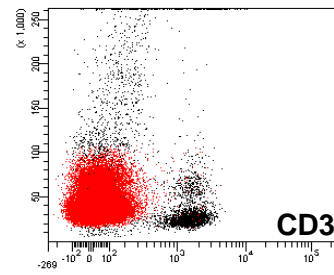
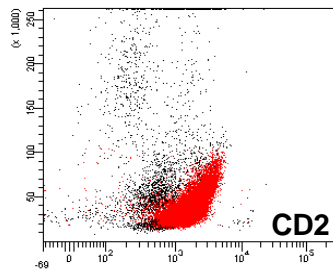
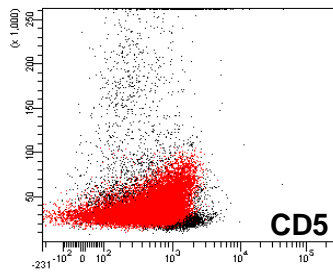
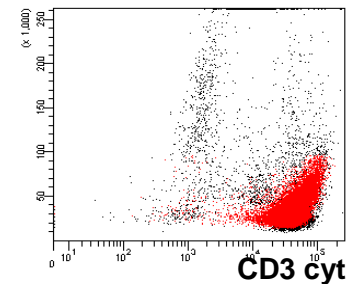
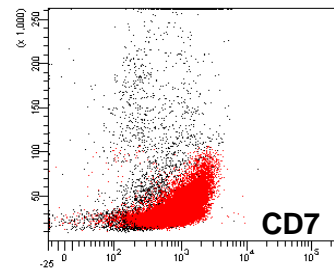
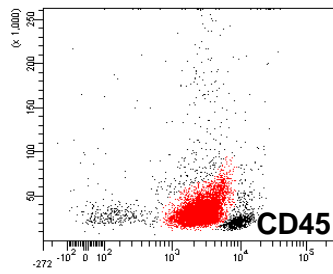
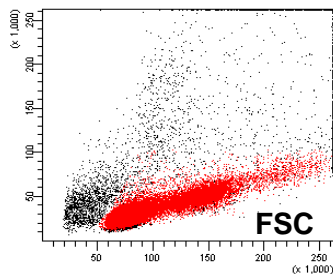


# Пациент Р. (спинномозговая жидкость)



# Пациент Ш.

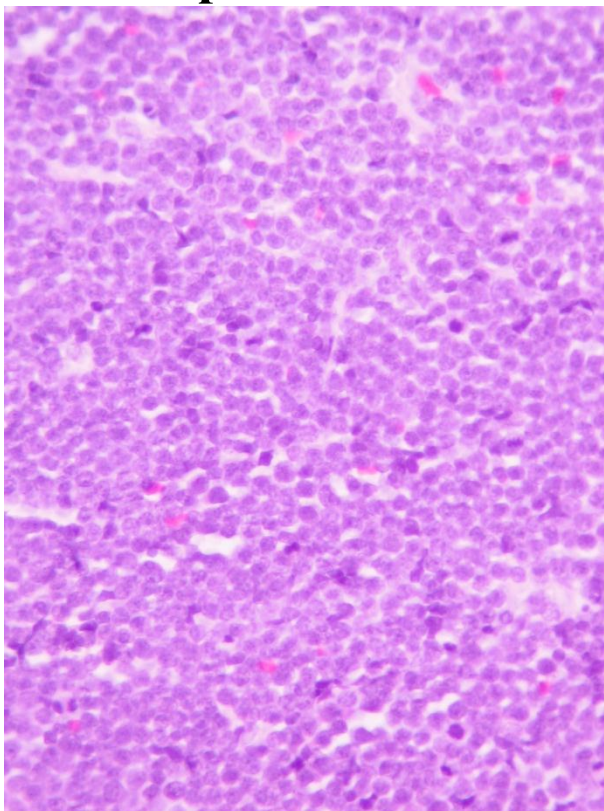
SSC



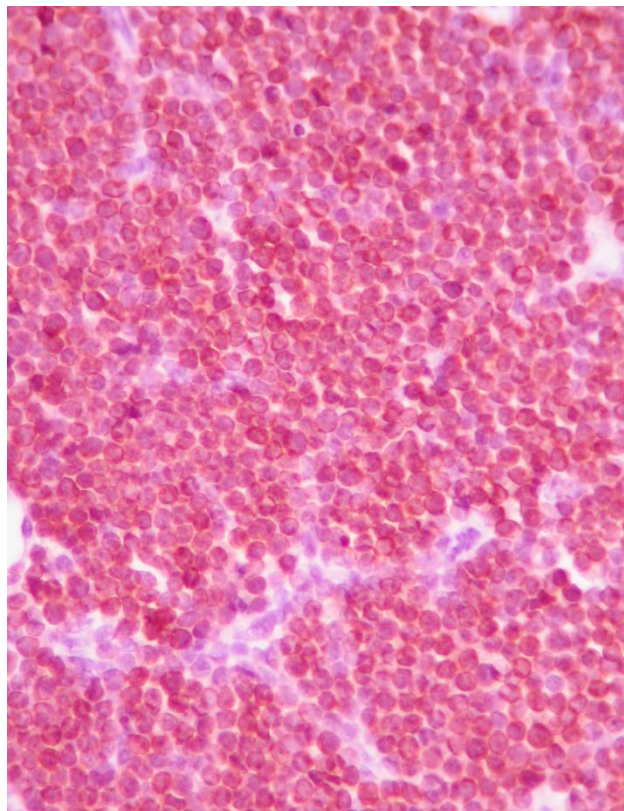
# Пациент Ш.

*иммуногистохимическое исследование*

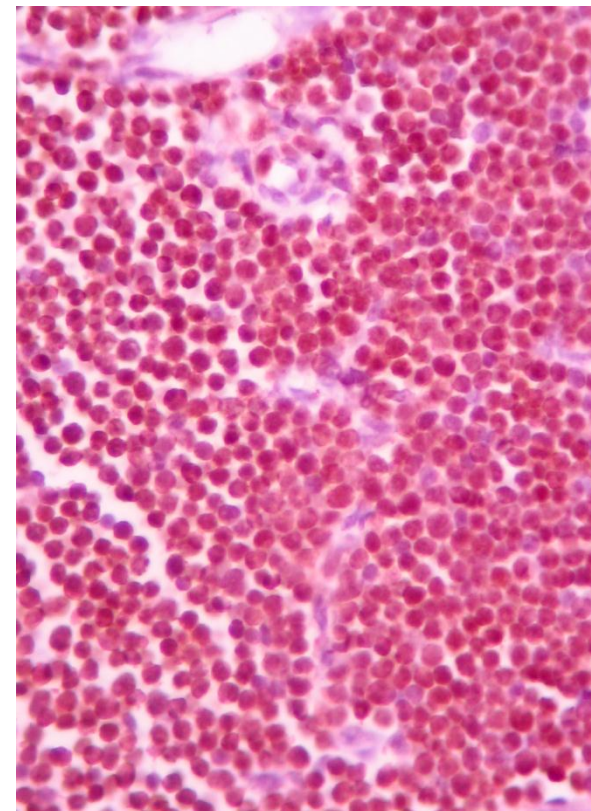
Окр. г+э. × 400



CD3. × 400



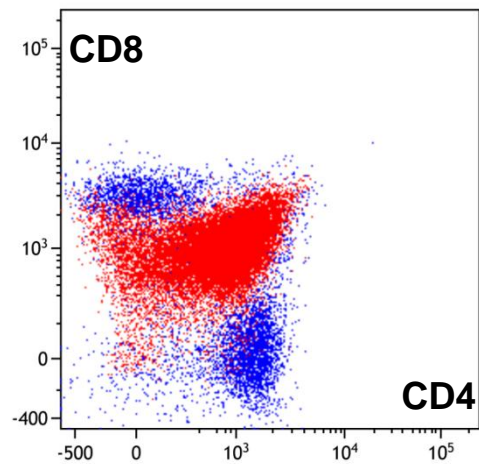
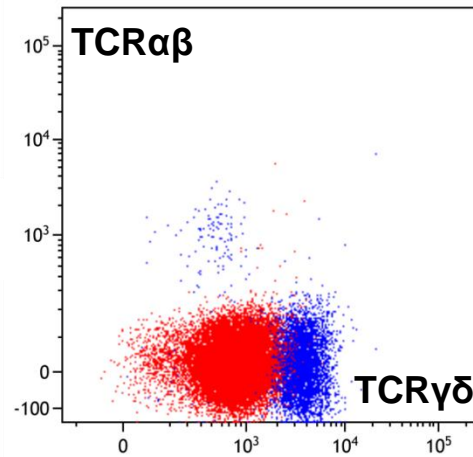
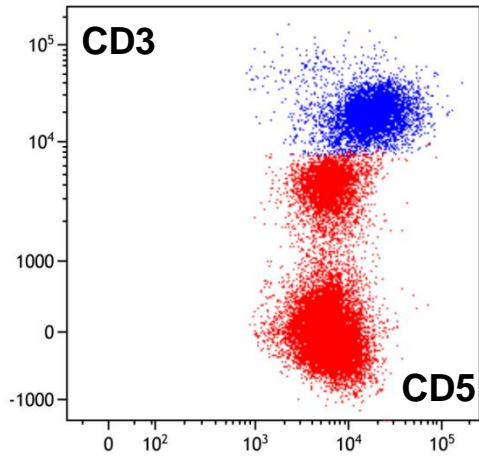
TdT. × 400



**Диагноз: Т-лимфобластная лимфома/лейкоз из  
клеток-предшественников**

# Пациент Н.

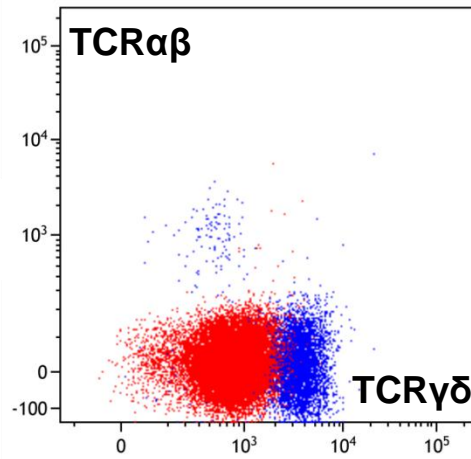
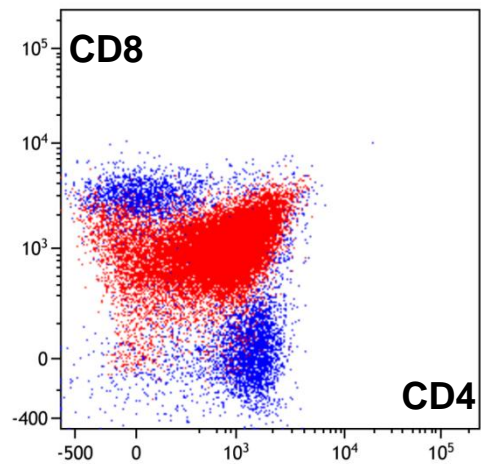
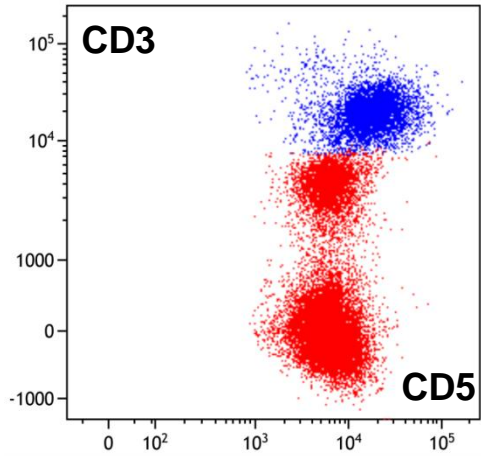
## Лимфоузел



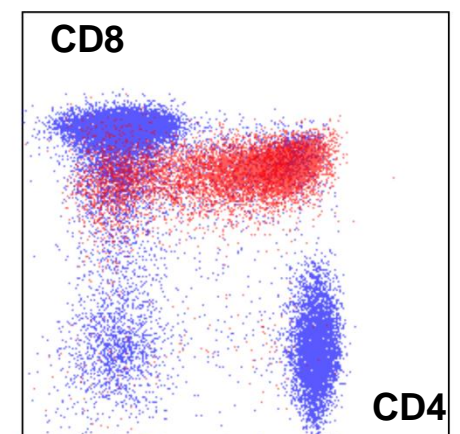
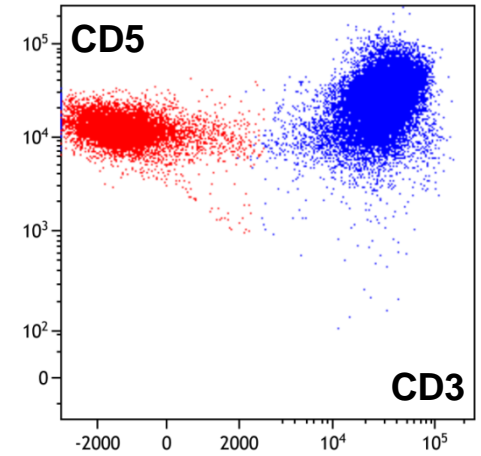


# Пациент Н.

## Лимфоузел

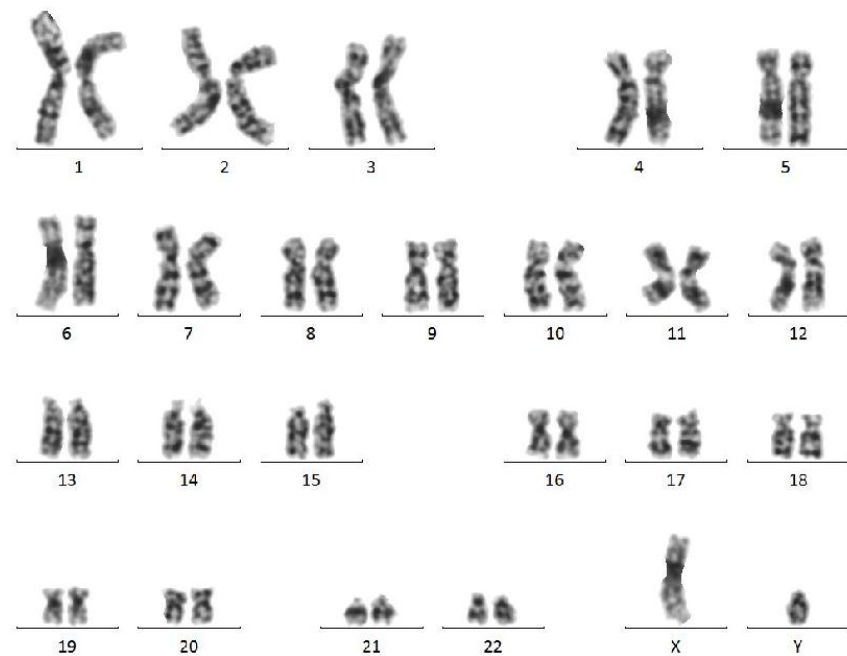
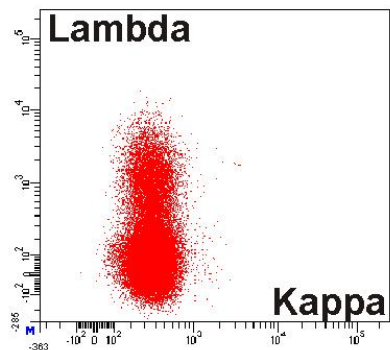
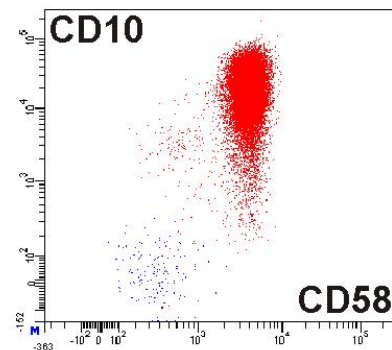
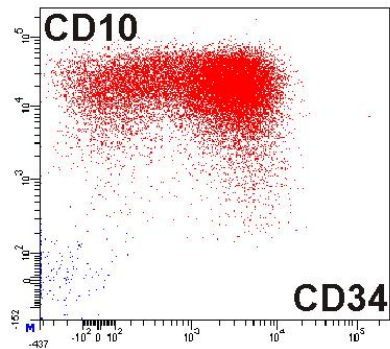
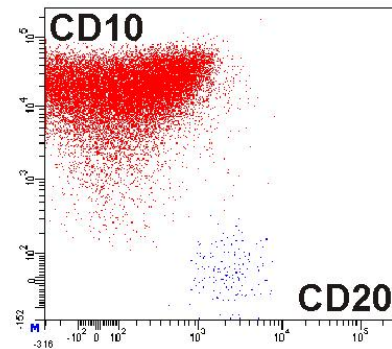
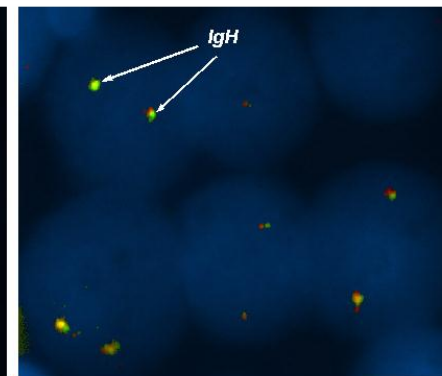
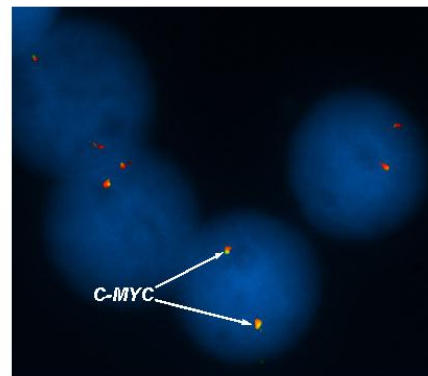
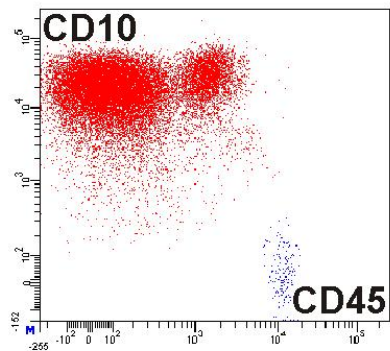
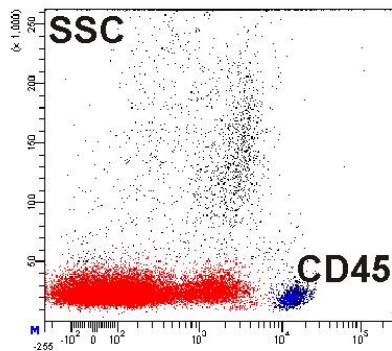


## Костный мозг

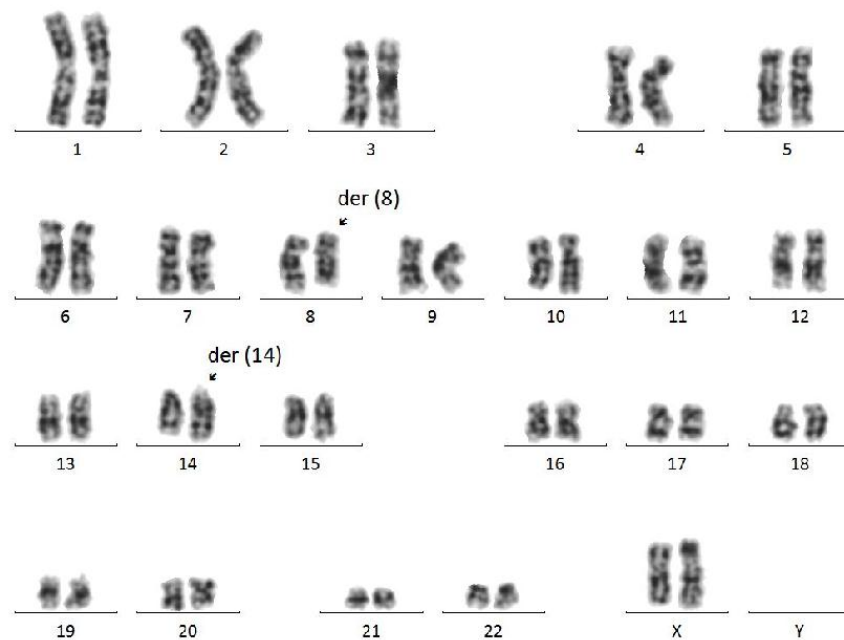
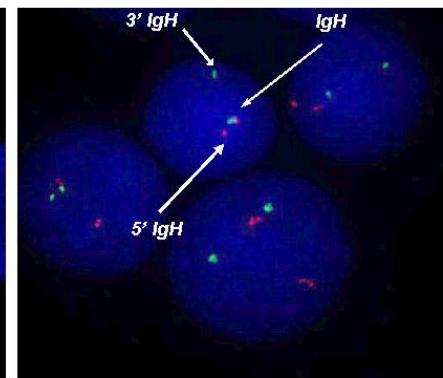
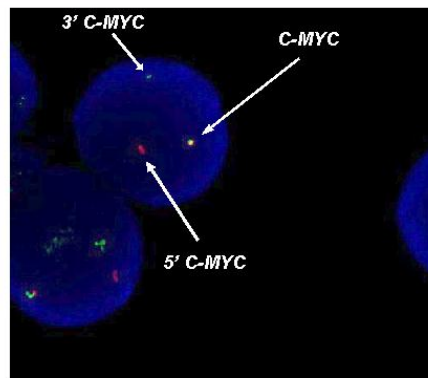
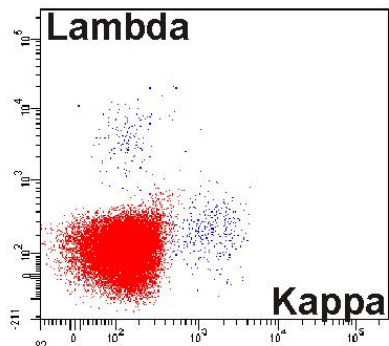
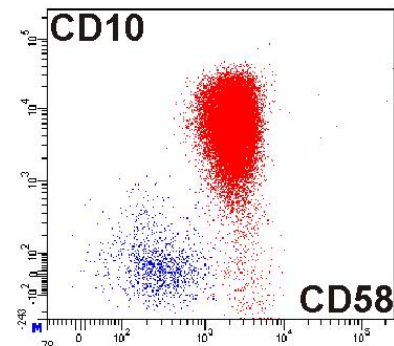
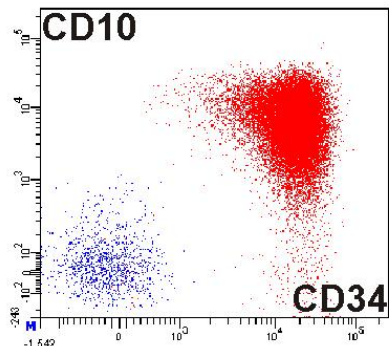
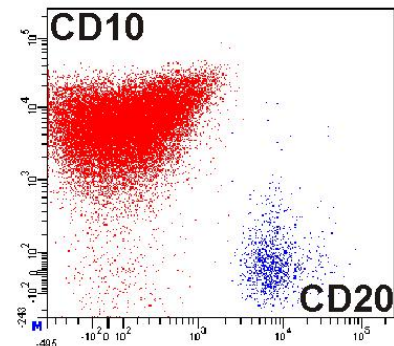
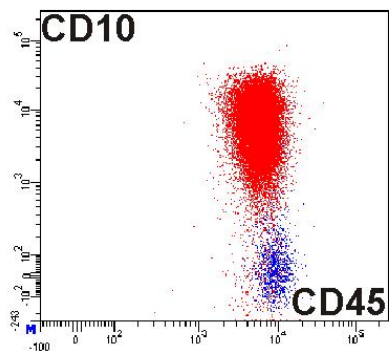
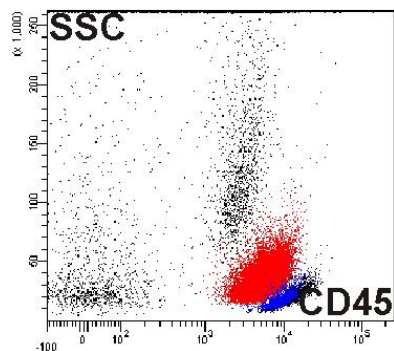


**ВІУ-ОЛЛ или лимфома Беркитта?**

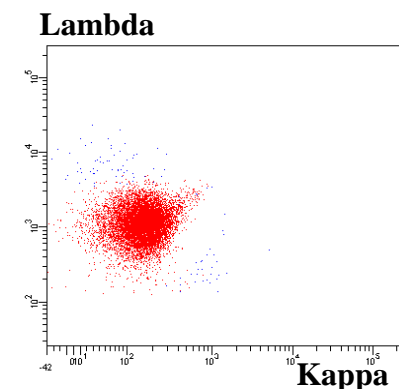
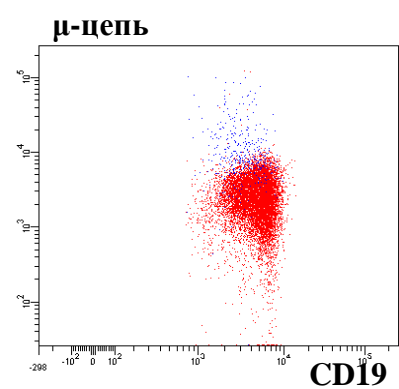
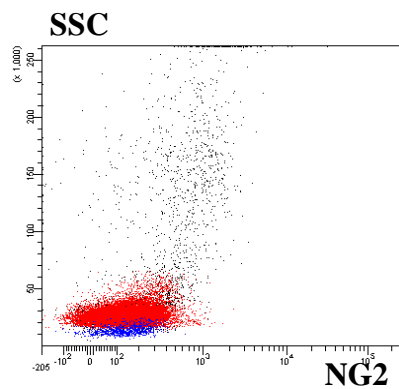
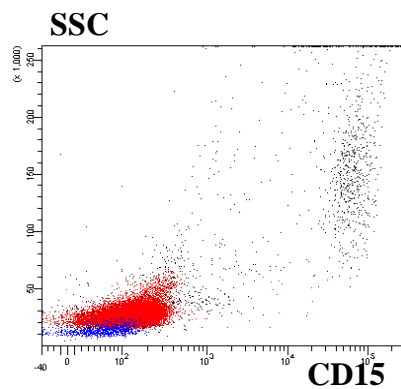
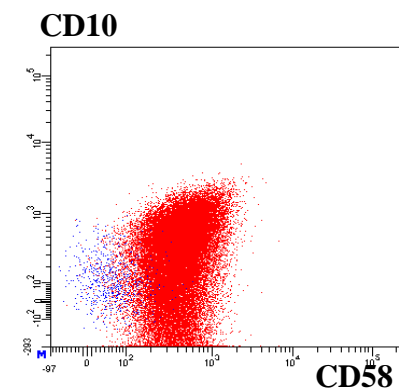
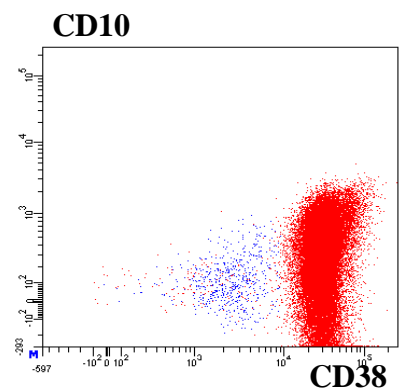
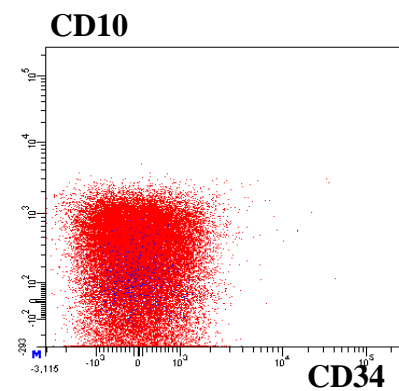
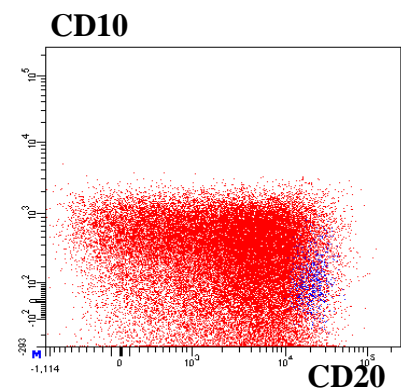
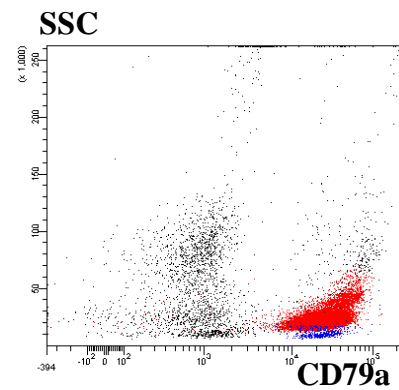
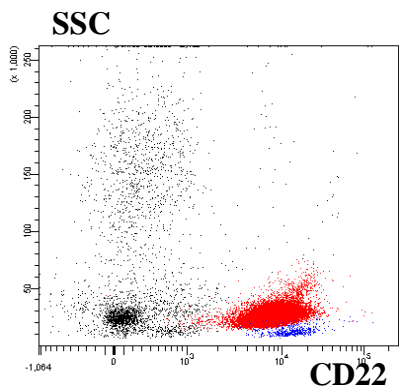
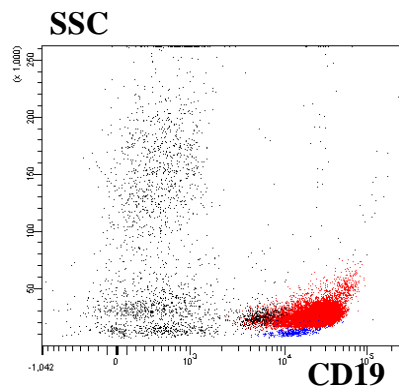
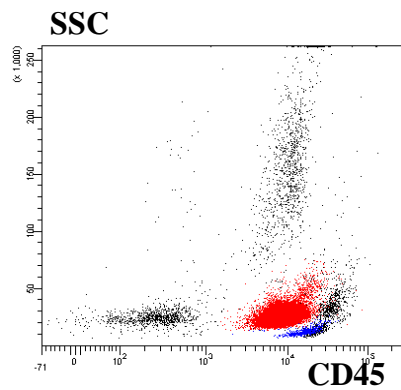
# Пациент К



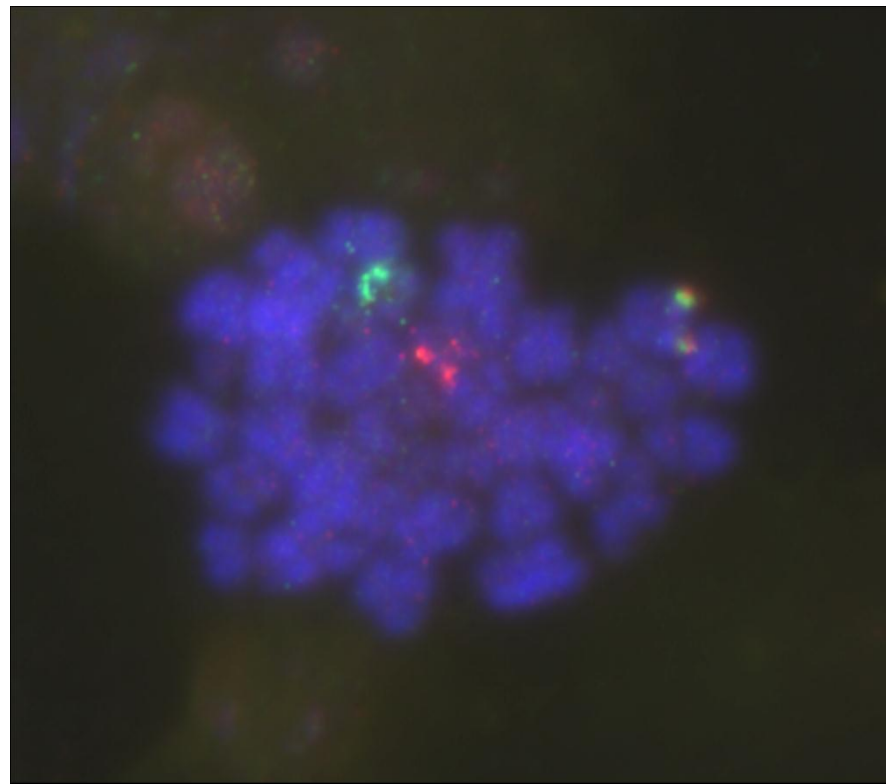
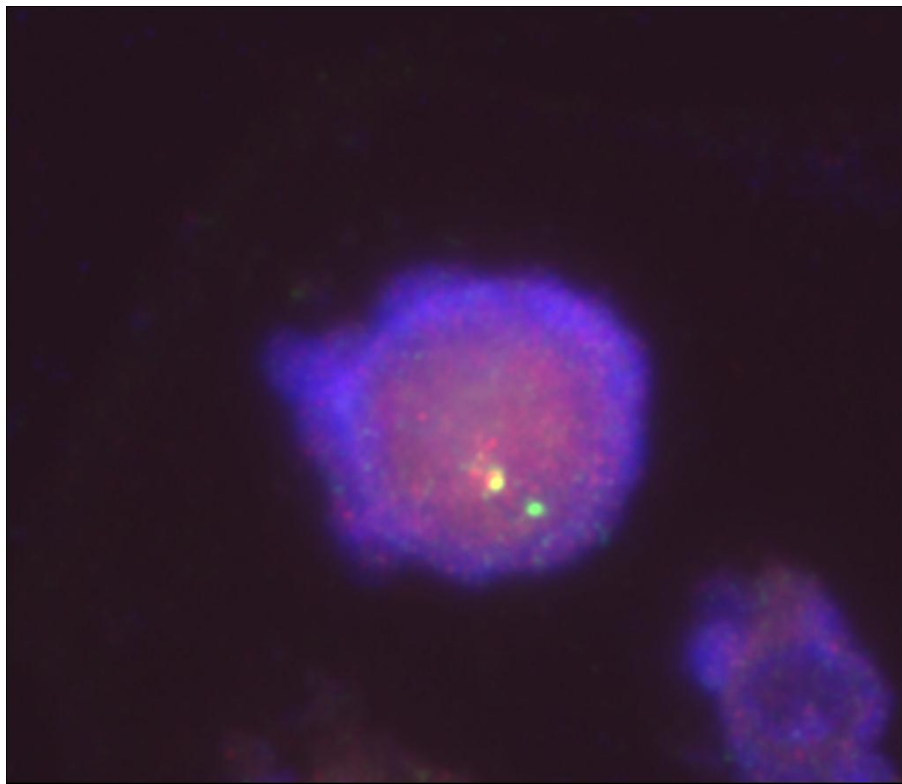
# Пациент С.



# Пациент А. (9 месяцев)

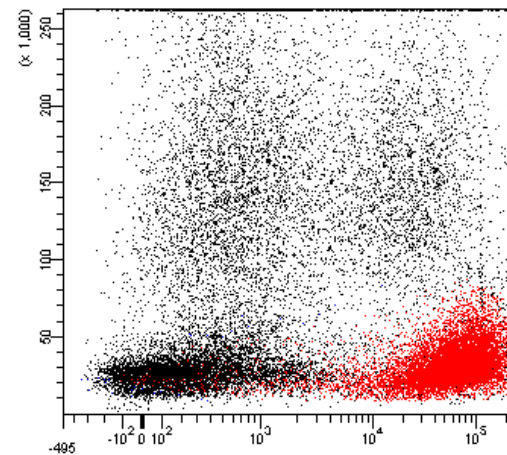
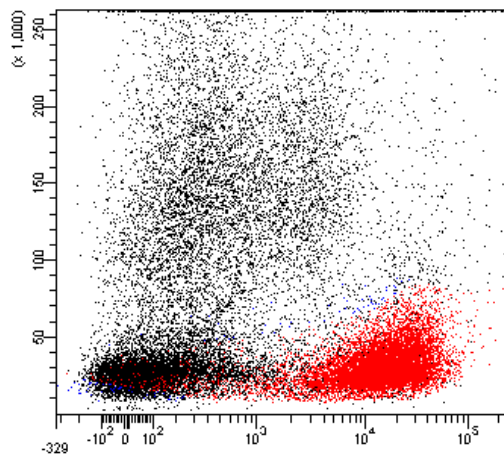
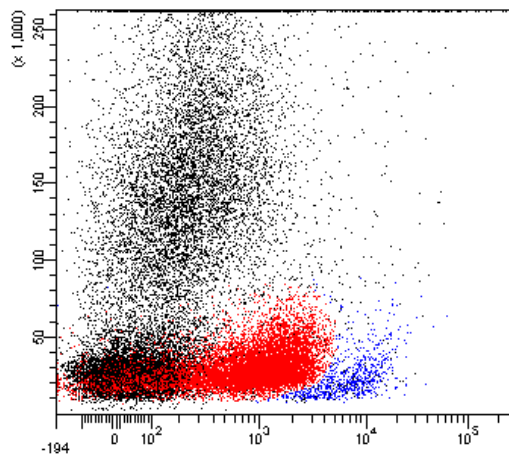


**Транслокация t(9;11)(p22;q23) с образованием химерного гена *MLL-MLLT3*, выявленная методом FISH**



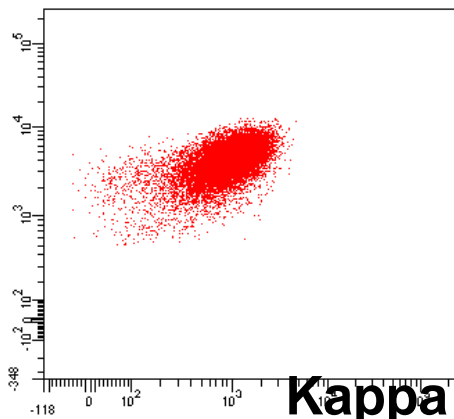
# Пациент П.

## SSC

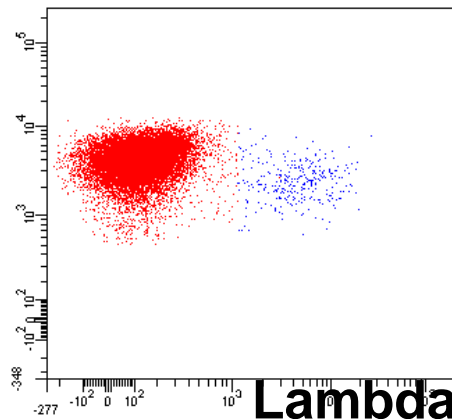


## IgM

## CD19

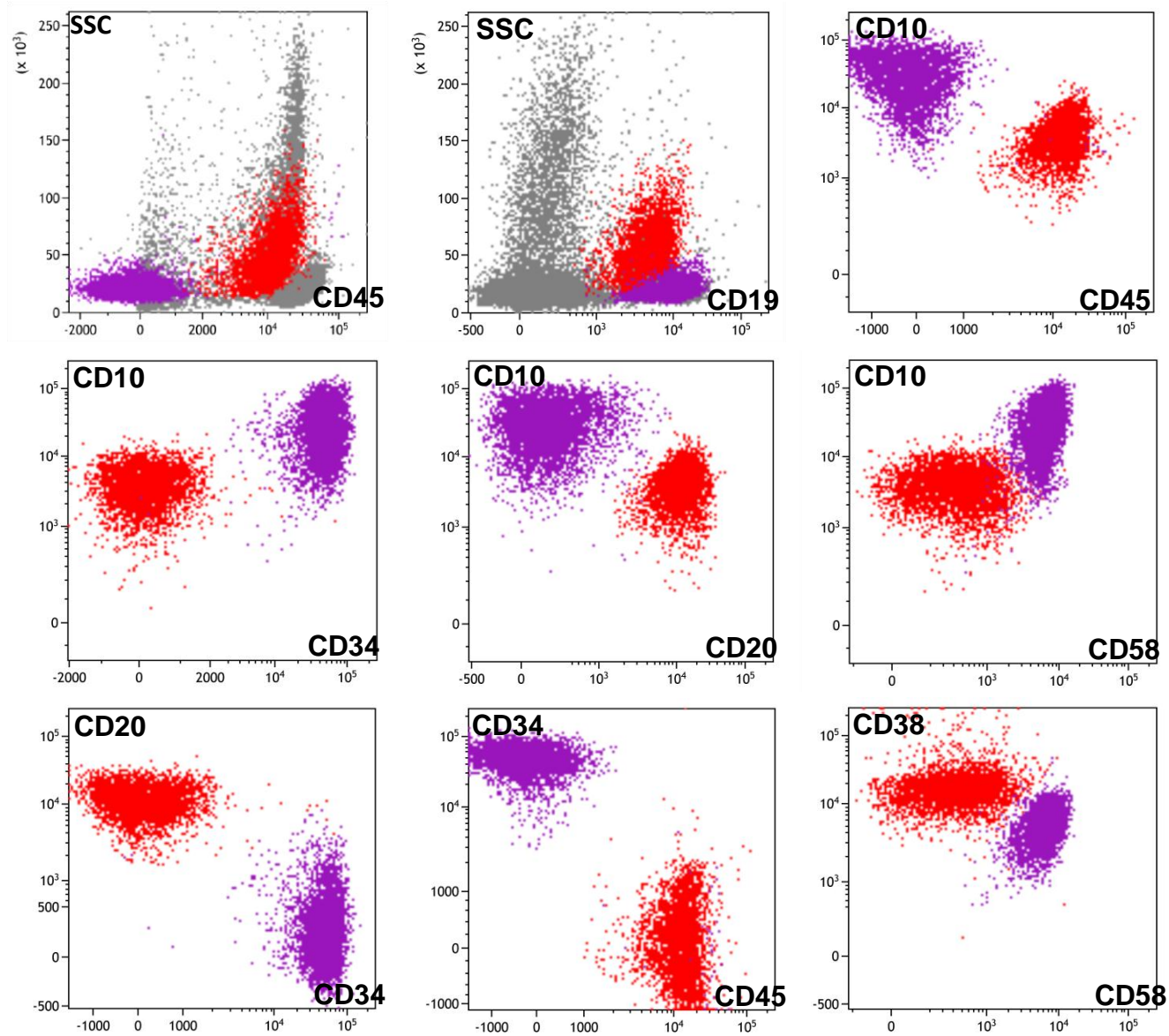


## Kappa



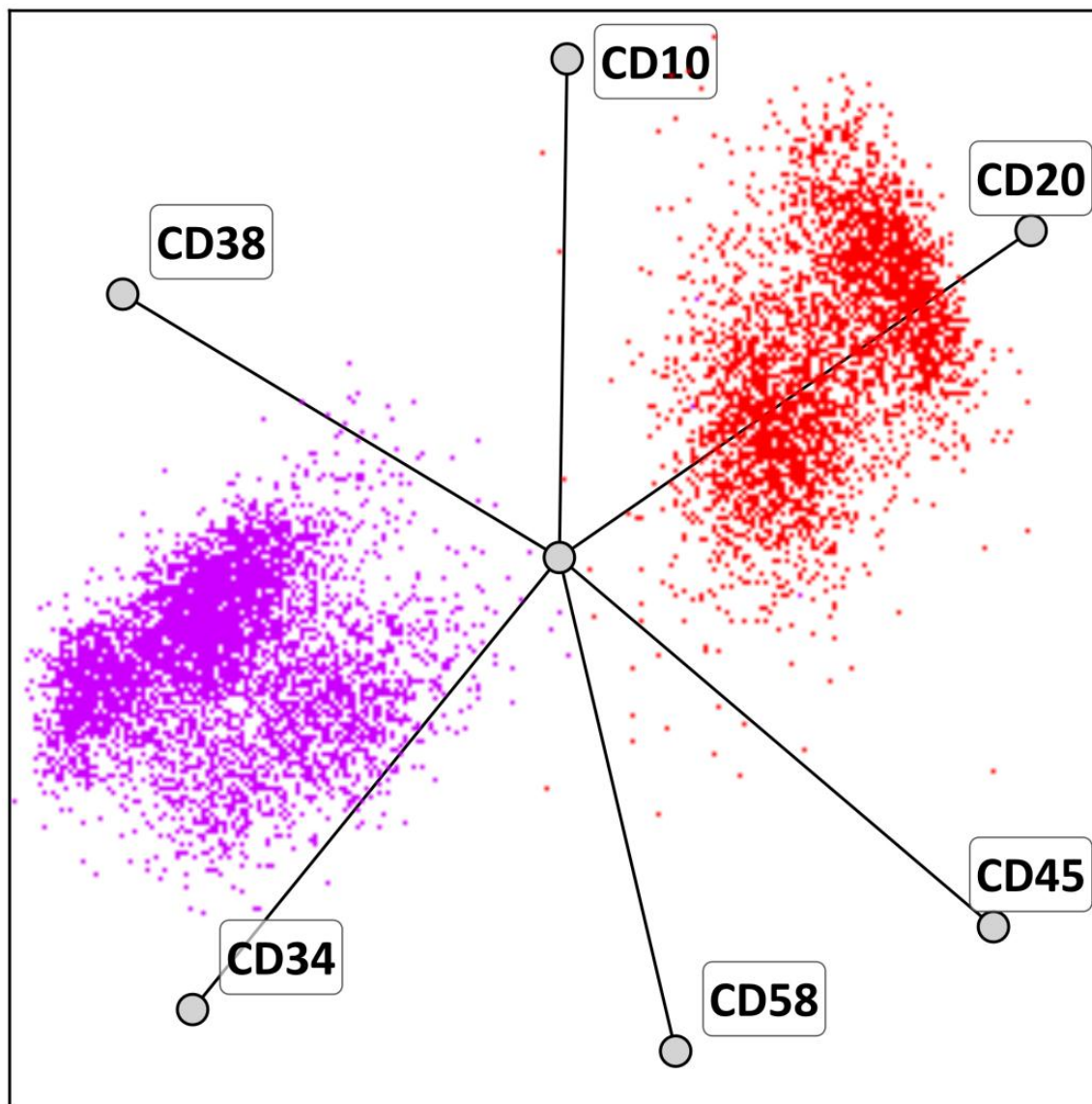
## Lambda

# Дифференциальная диагностика лимфомы Беркитта и ОЛЛ



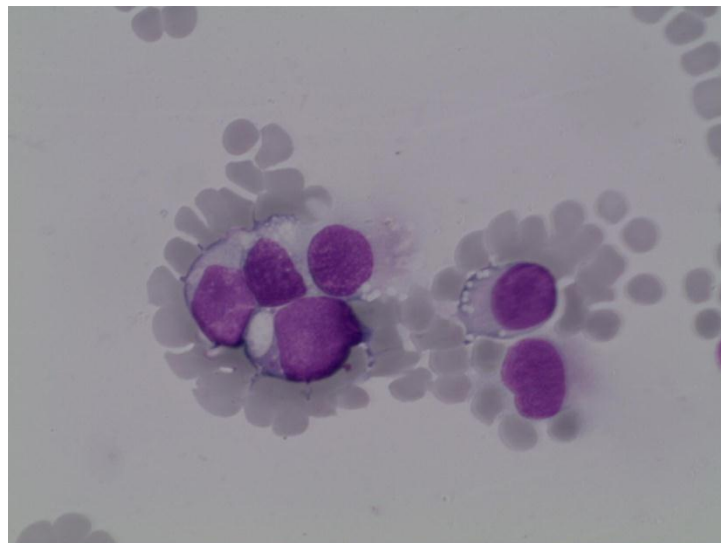
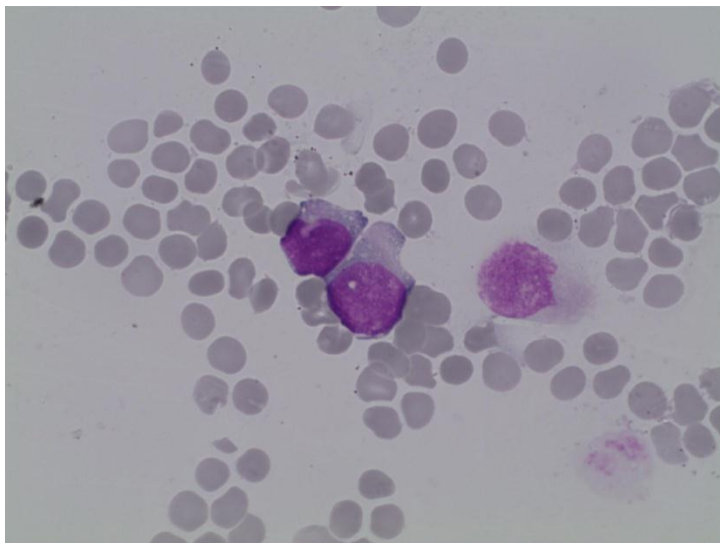
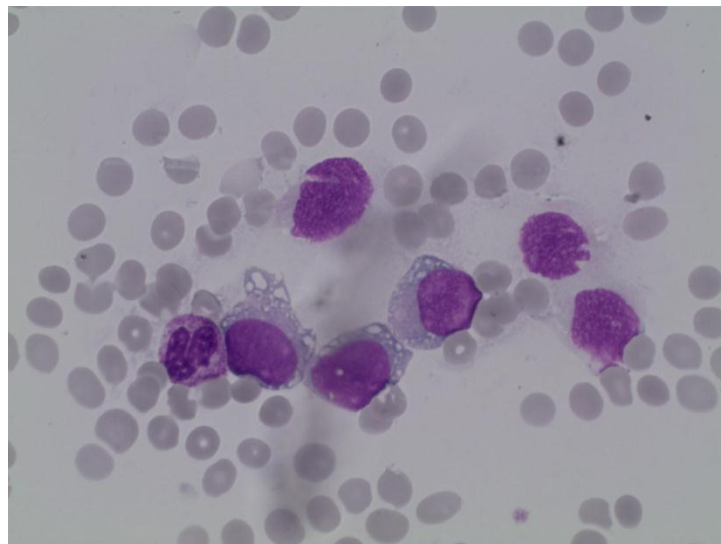
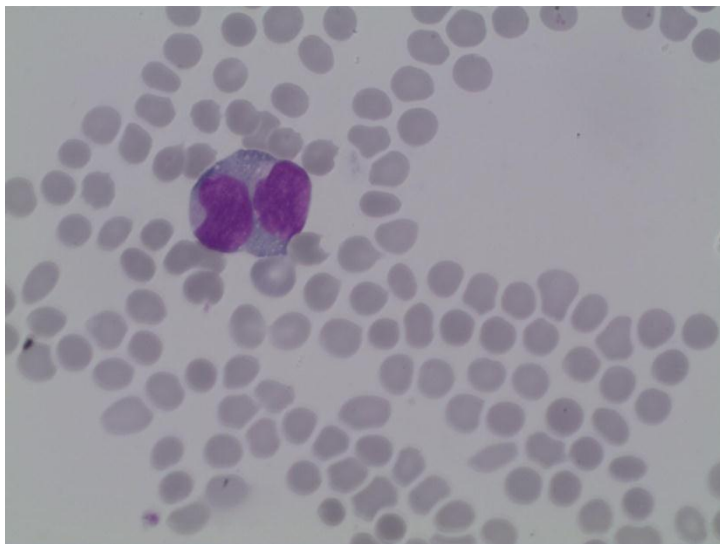


# Дифференциальная диагностика лимфомы Беркитта и ОЛЛ



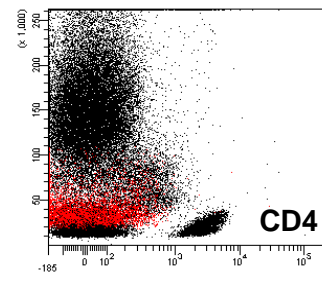
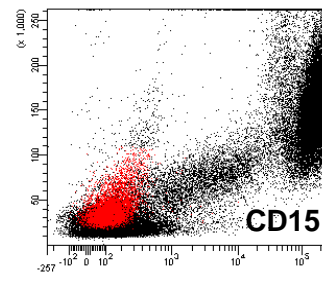
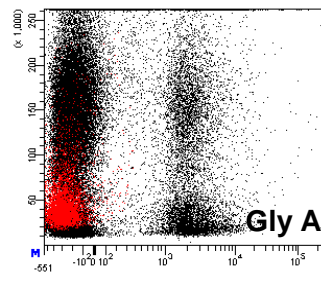
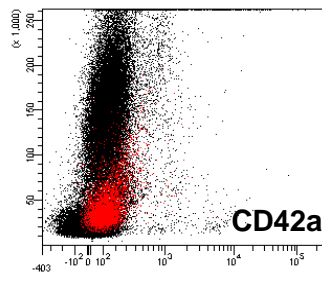
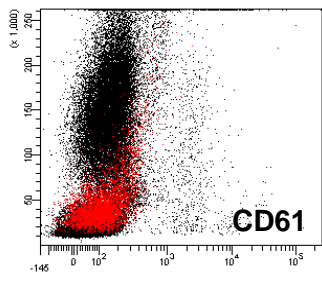
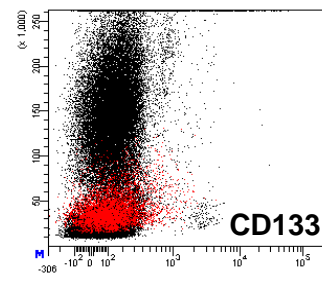
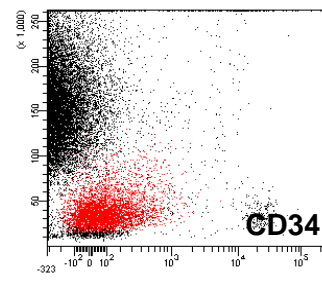
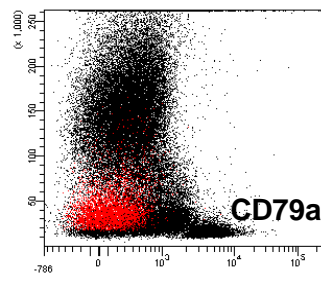
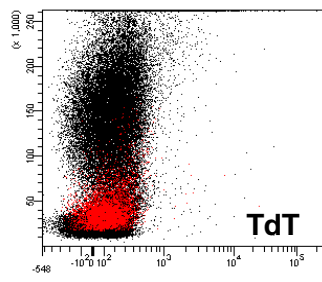
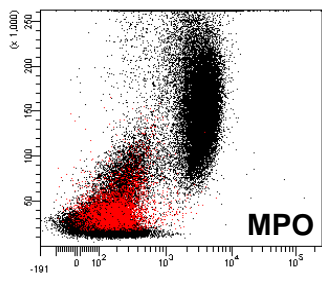
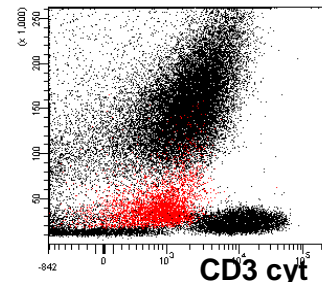
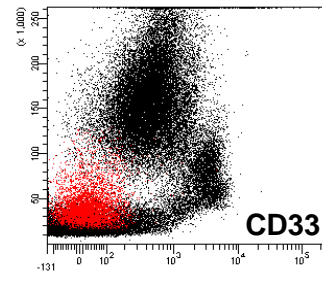
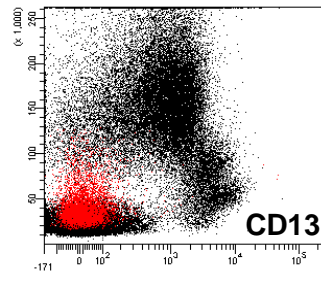
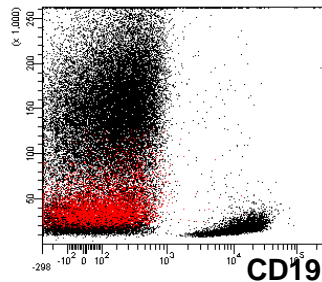
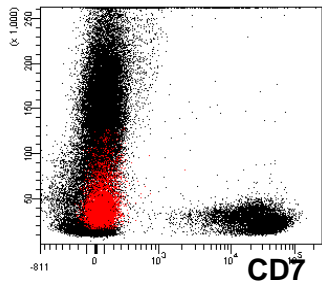
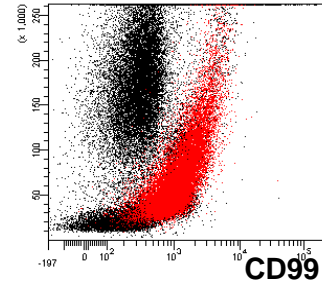
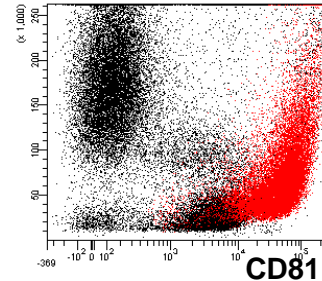
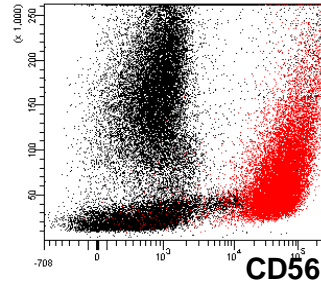
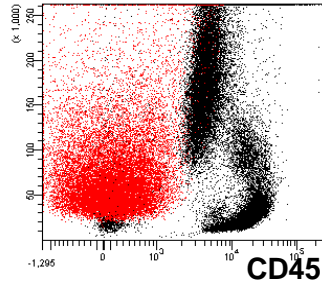
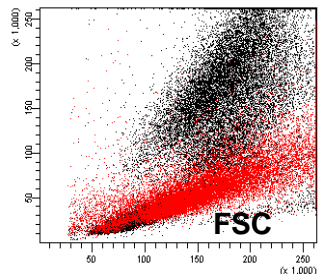
# **Дифференциальная диагностика ОЛ и солидных опухолей**

# Пациент Г.



# Пациент Г.

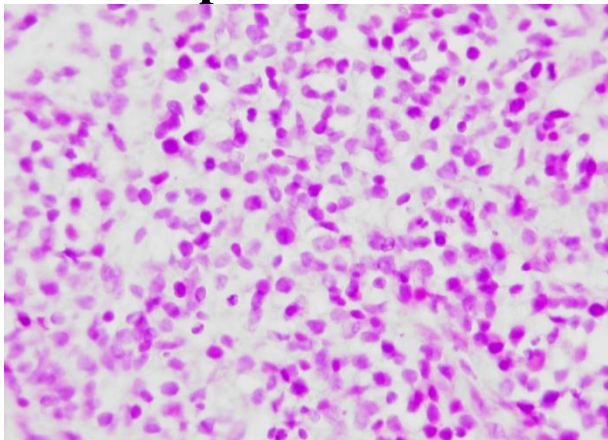
SSC



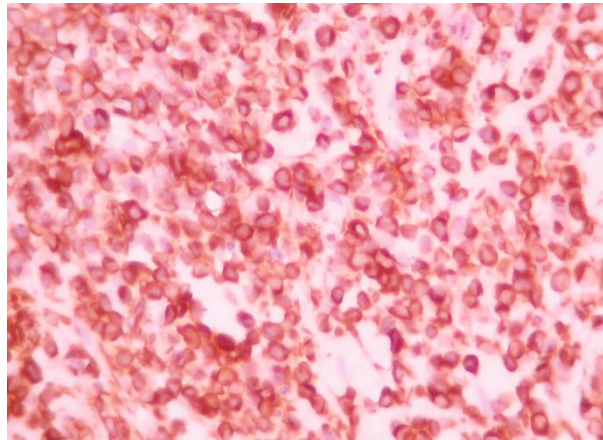
# Пациент Г.

## *иммуногистохимическое исследование*

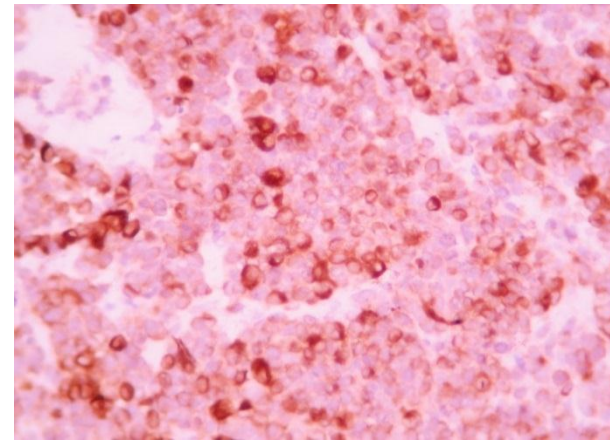
**Окр. г+э. × 400**



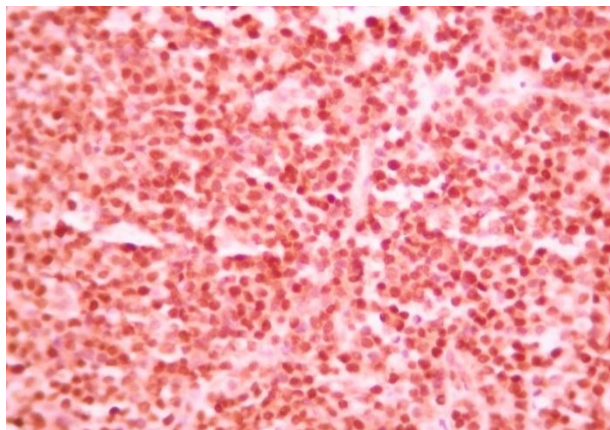
**Vimentin. × 400**



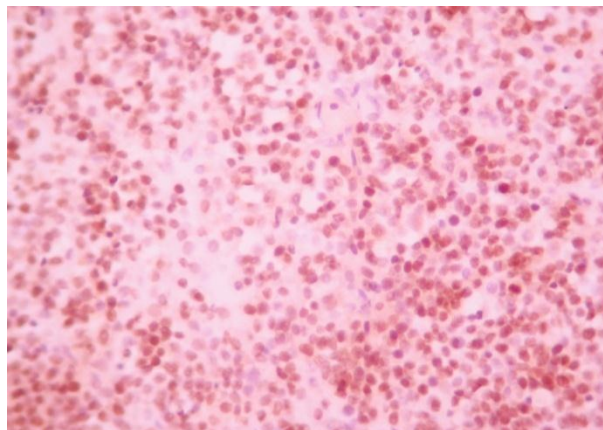
**Desmin. × 400**



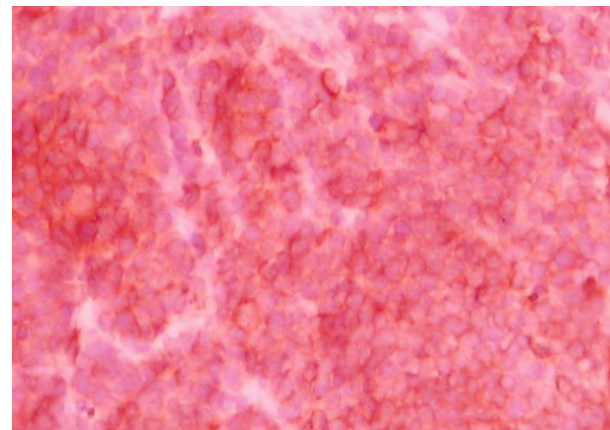
**Myogenin. × 400**



**MyoD1. × 400**



**CD99. × 400**



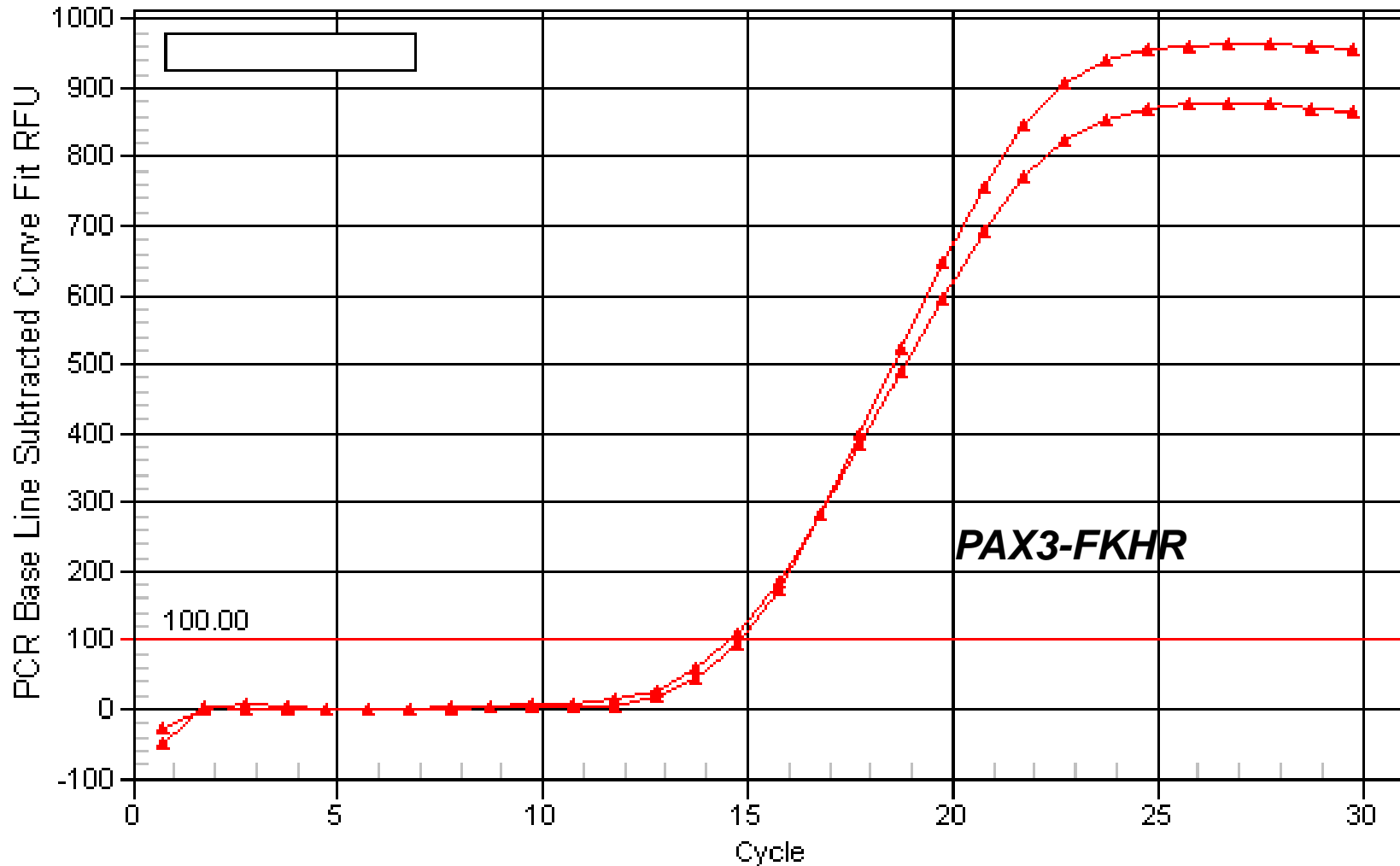
**Диагноз: альвеолярная рабдомиосаркома**

# Пациент Г.

*молекулярно-генетическое исследование*

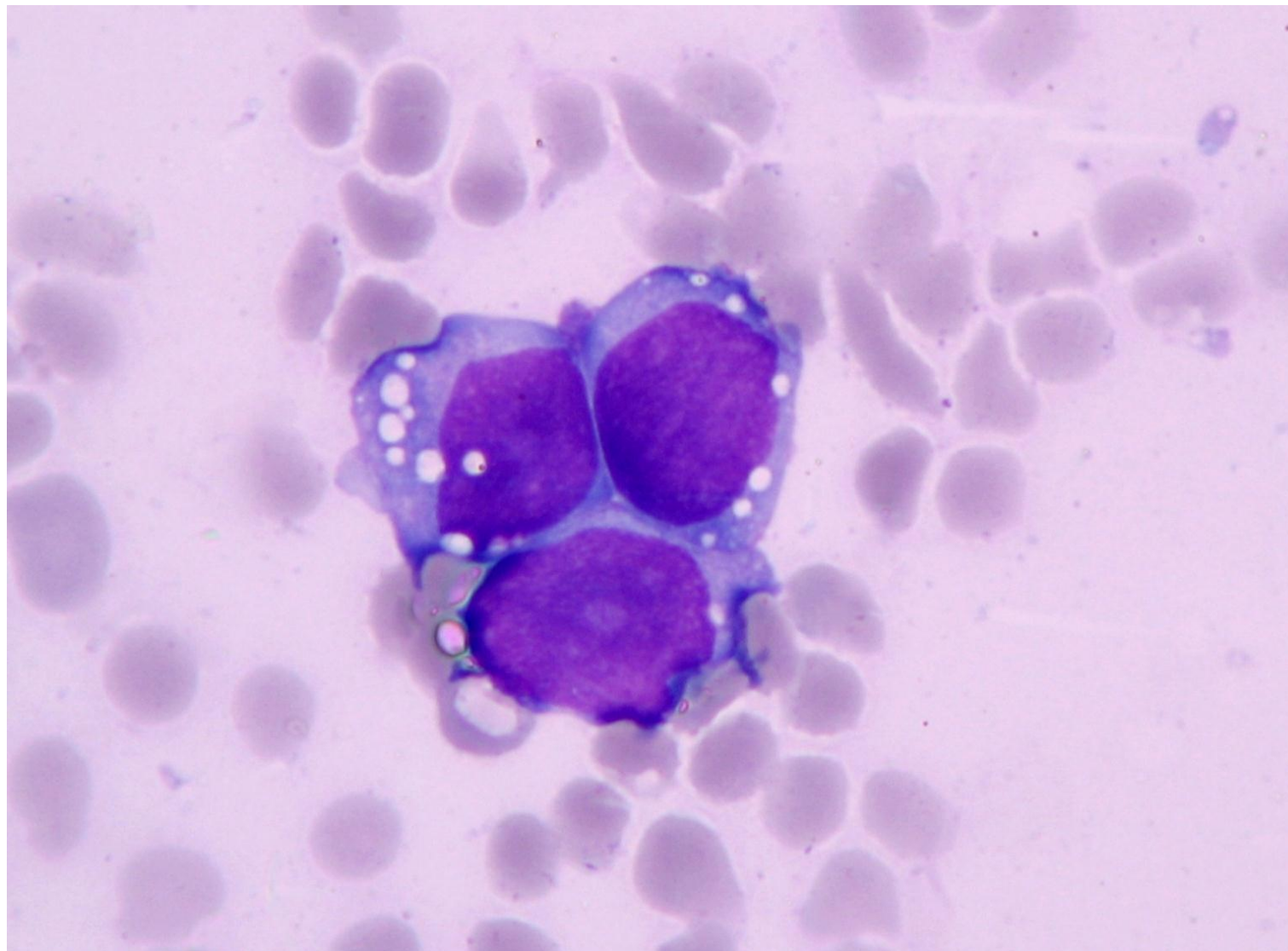
**t(2;13)(q37;q14)**

Amplification Chart



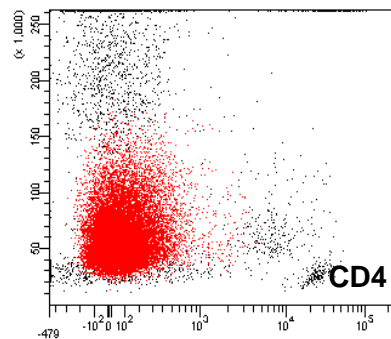
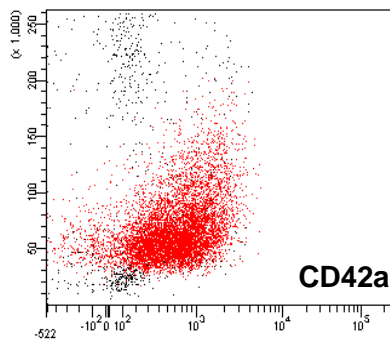
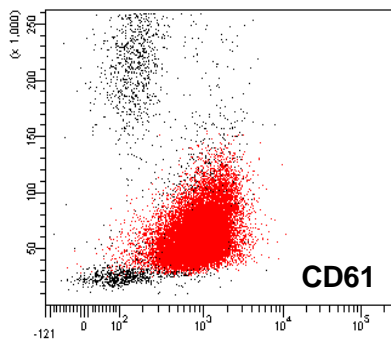
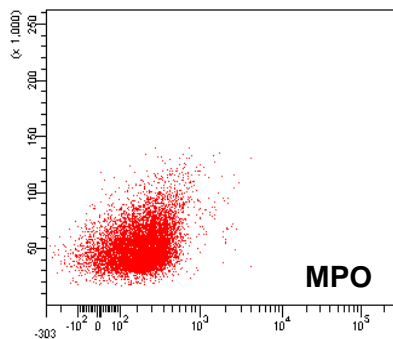
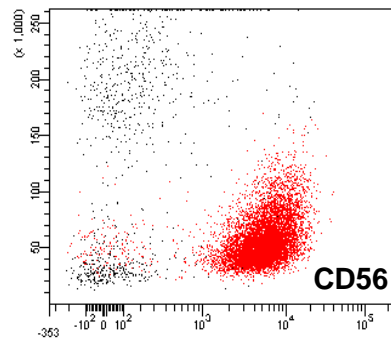
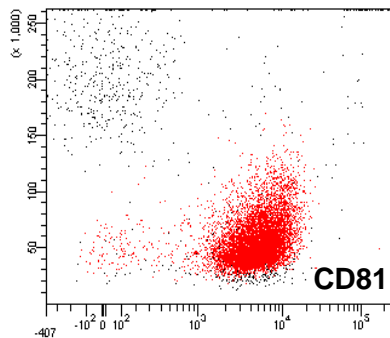
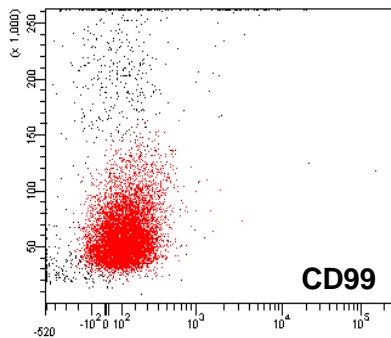
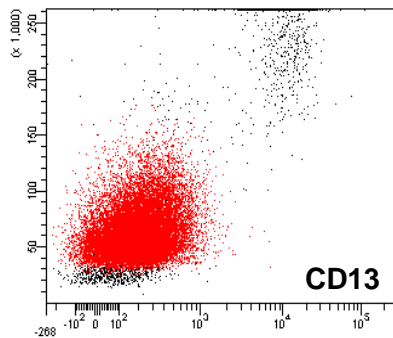
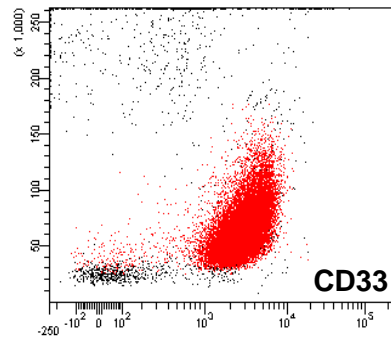
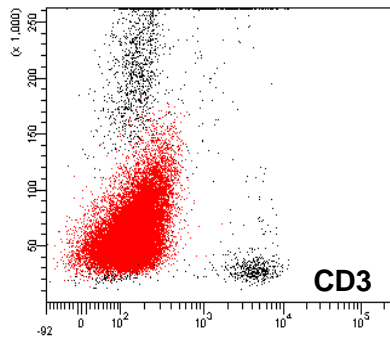
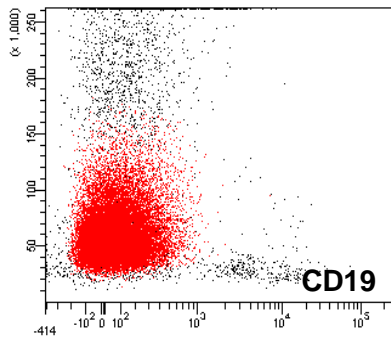
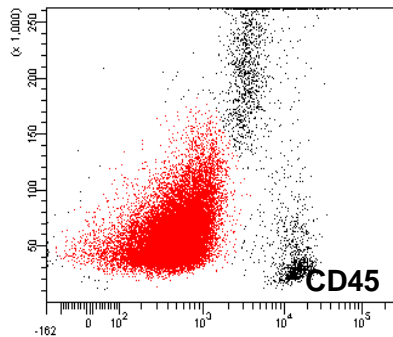
# Пациент С.

*цитологическое исследование*



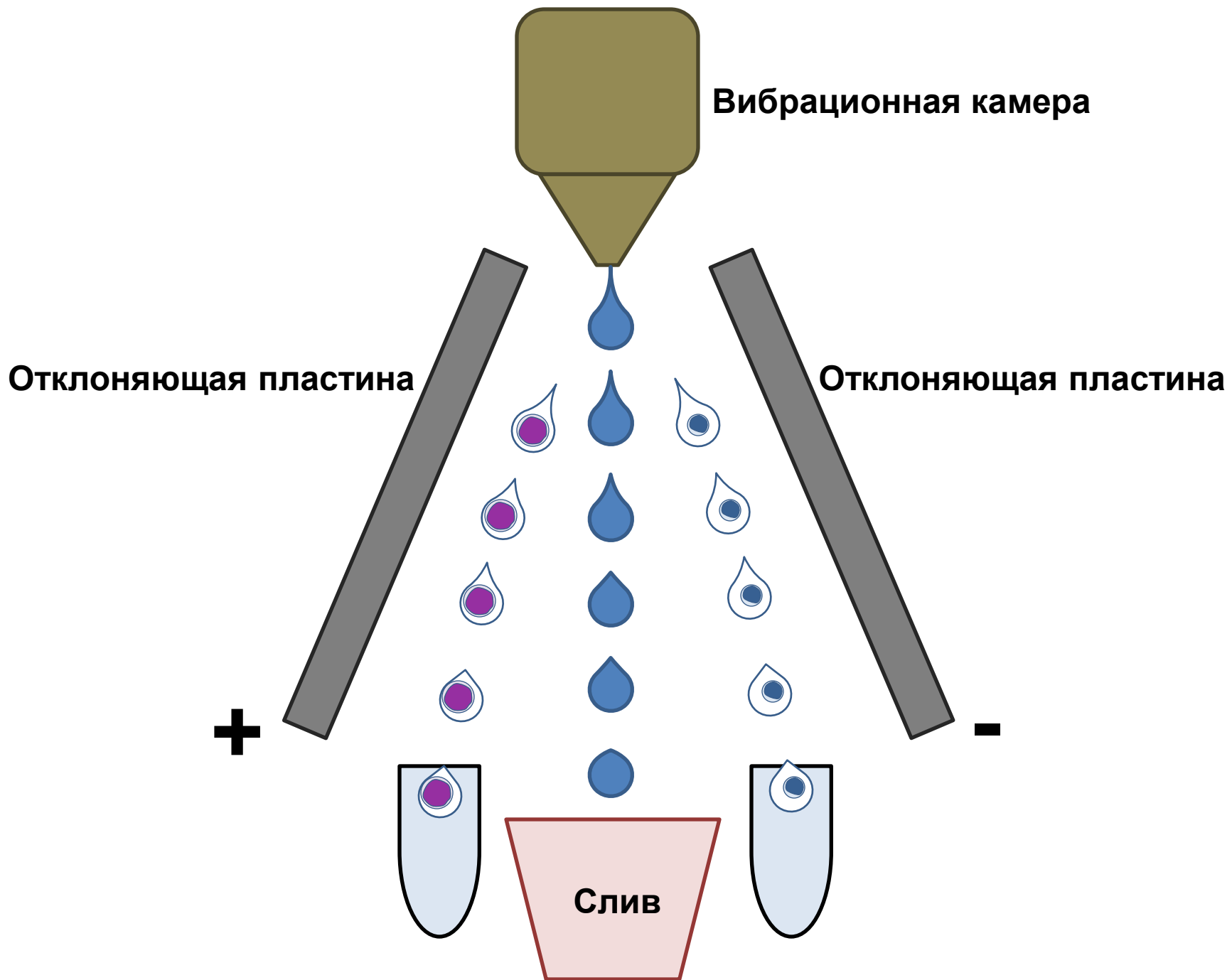
# Пациент С.

SSC

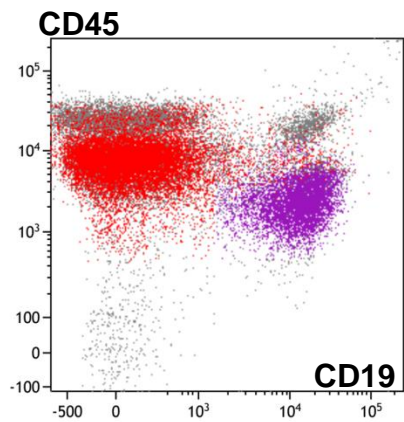
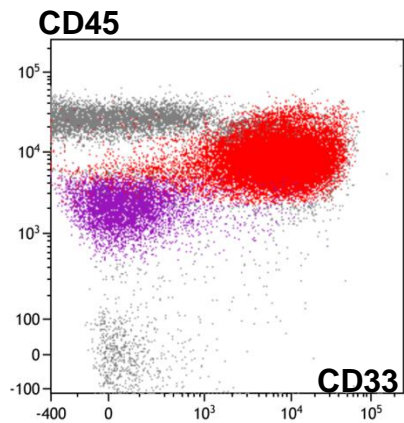




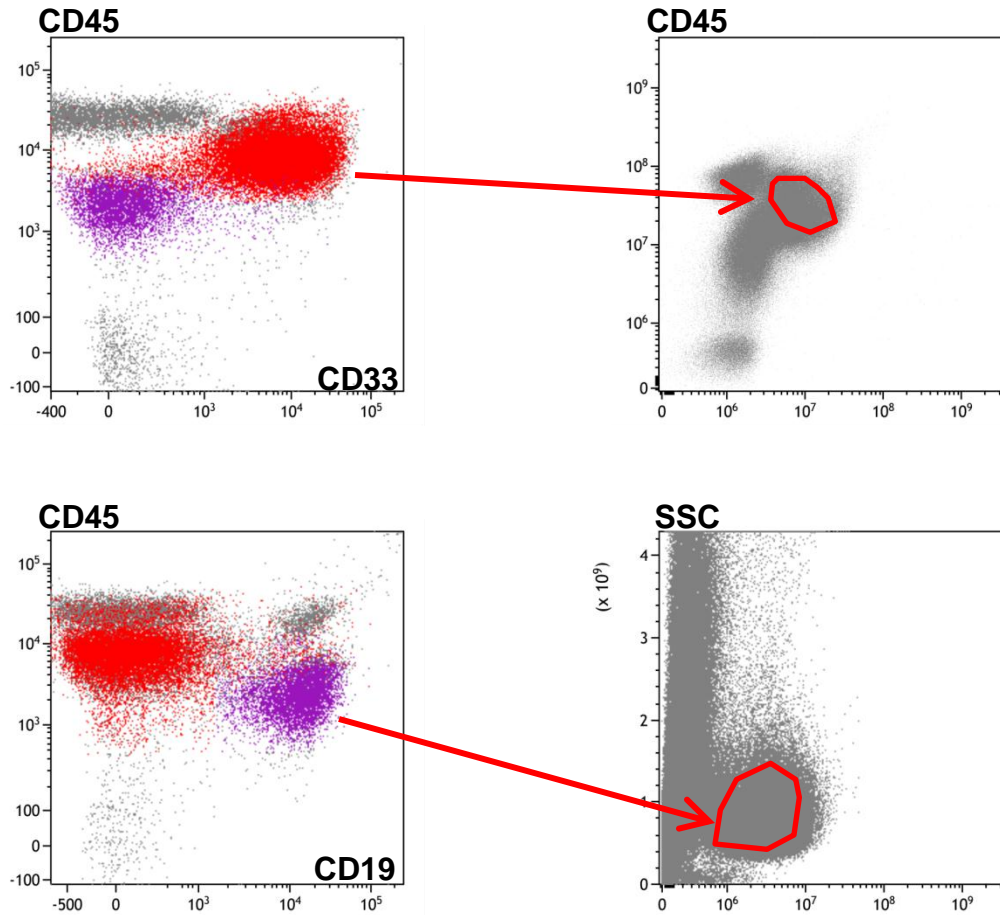
# **Сортировка клеток**



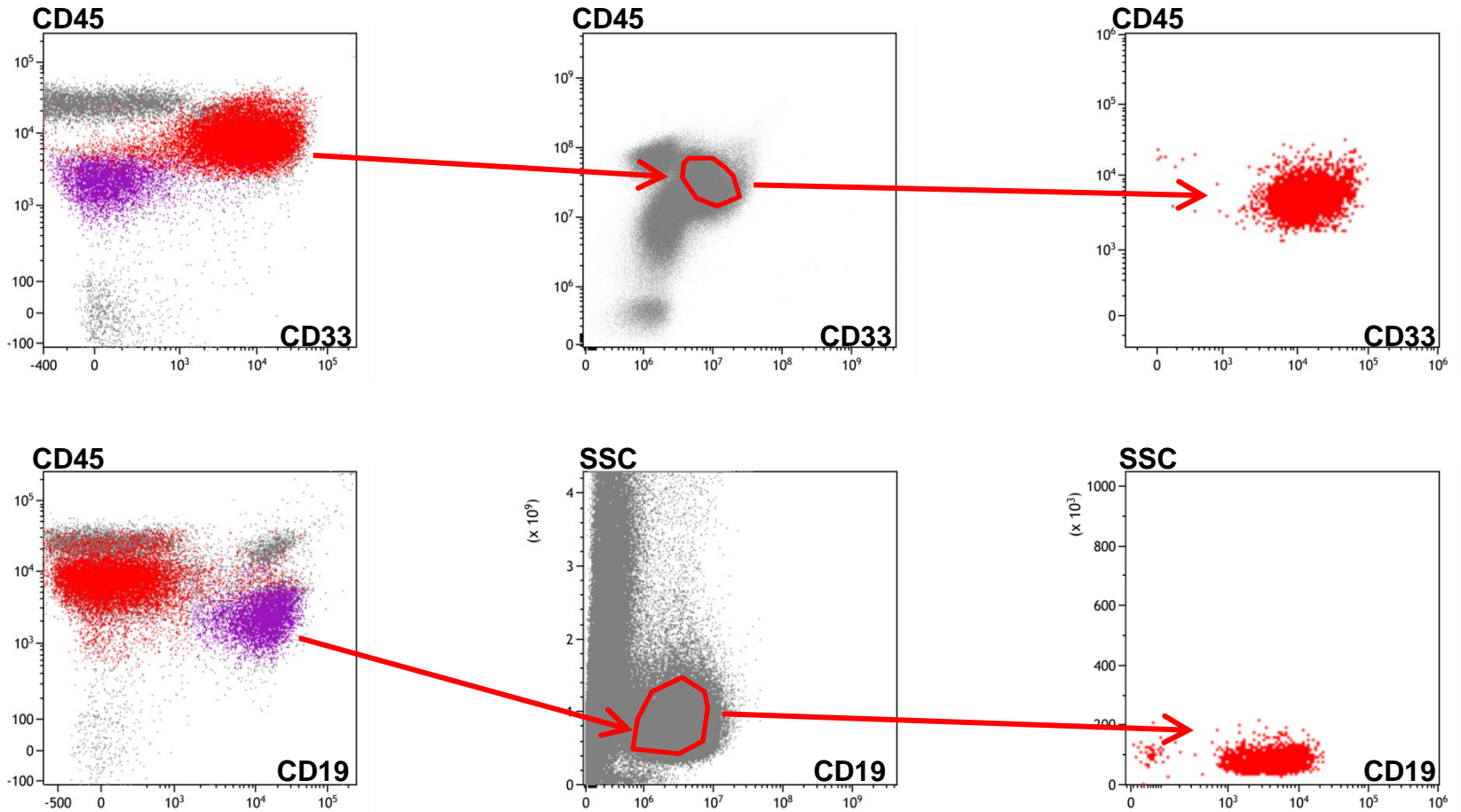
# Острый билинейный лейкоз

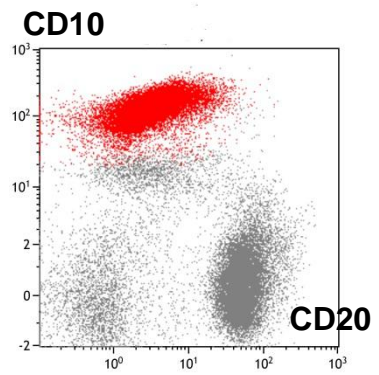
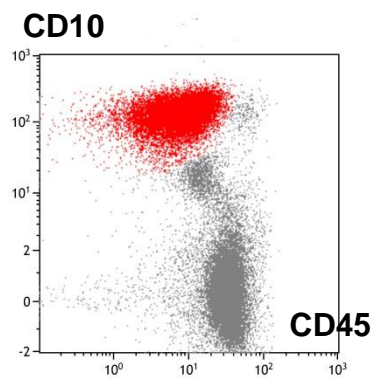
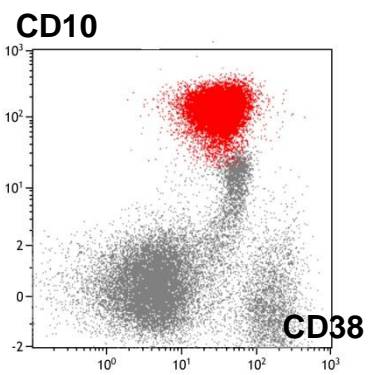


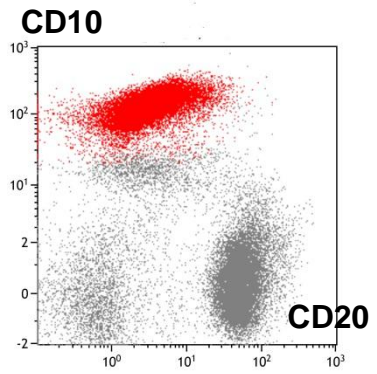

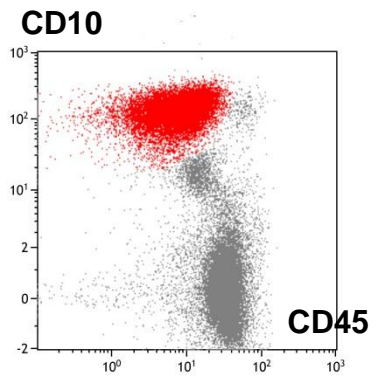
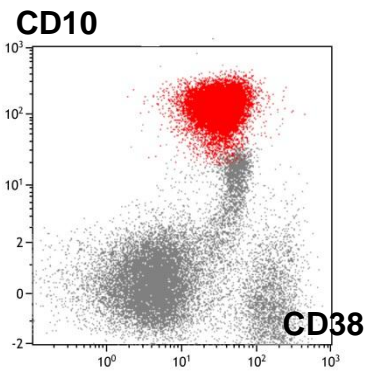
# Острый билинейный лейкоз

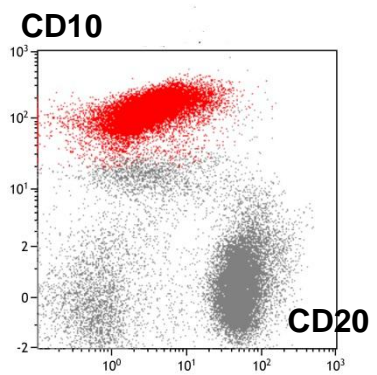
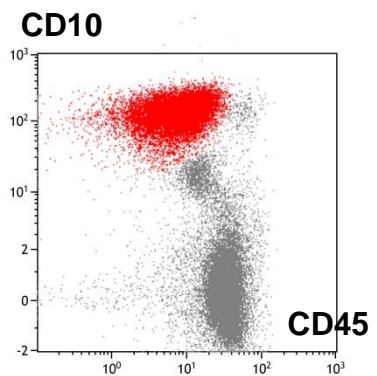
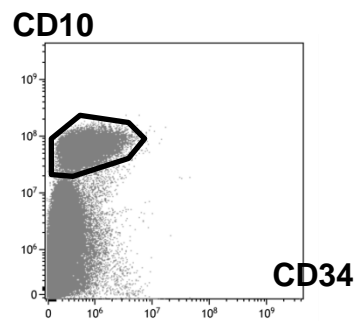
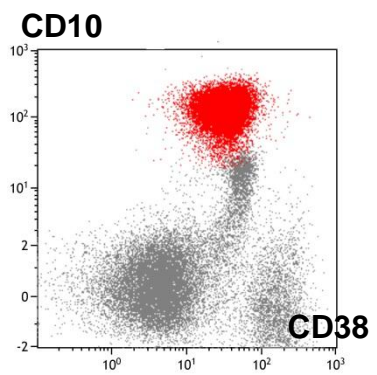


# Острый билинейный лейкоз

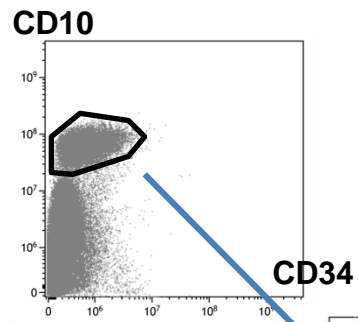

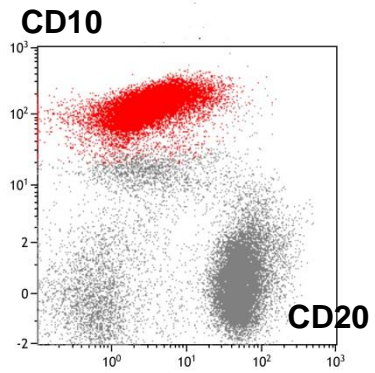
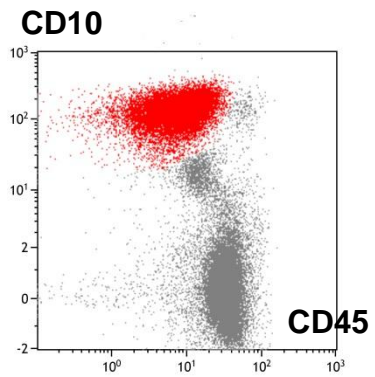
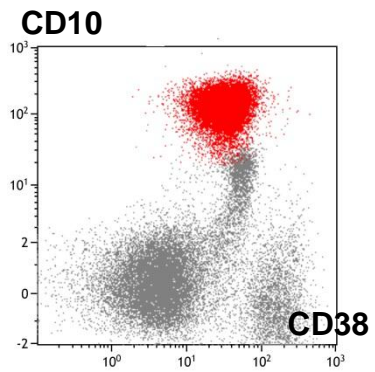




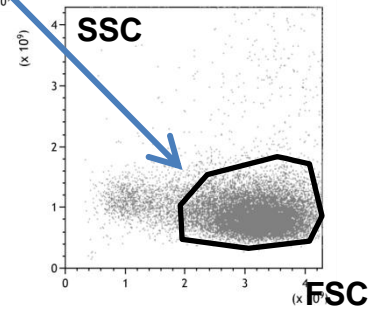


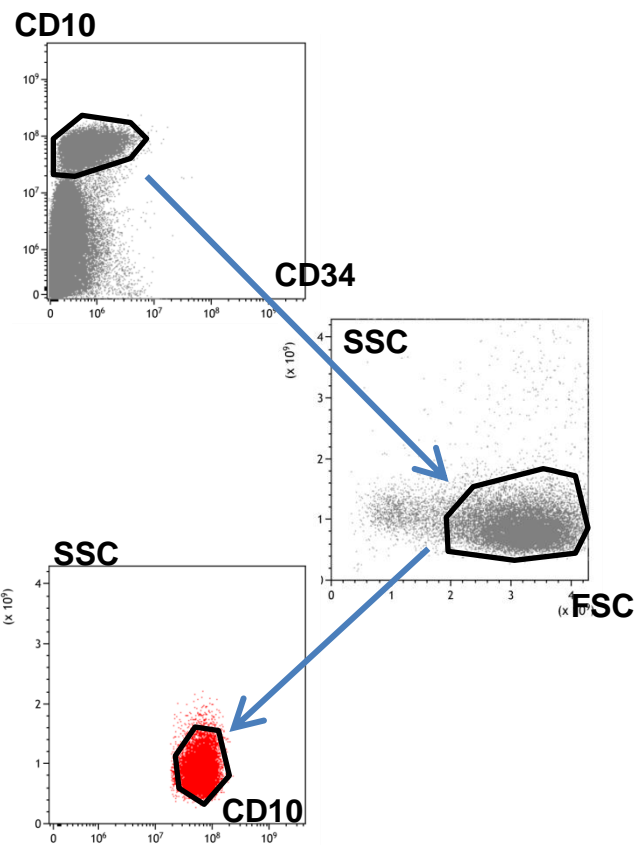
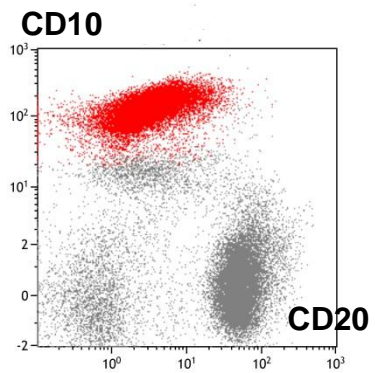
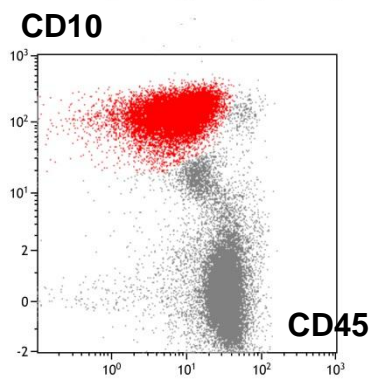
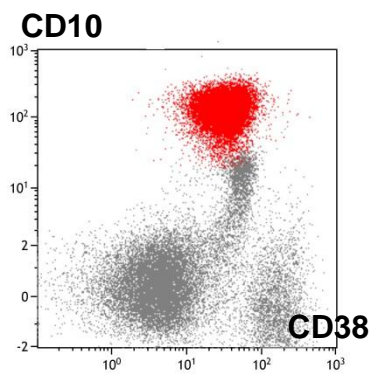


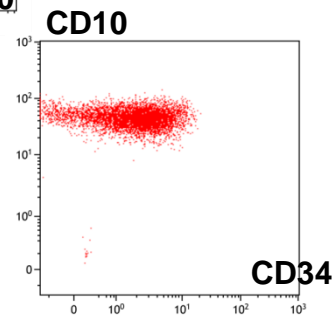
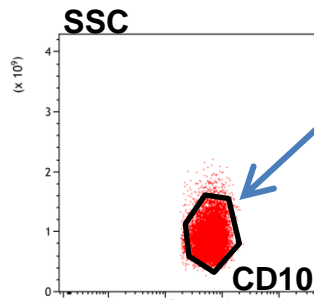
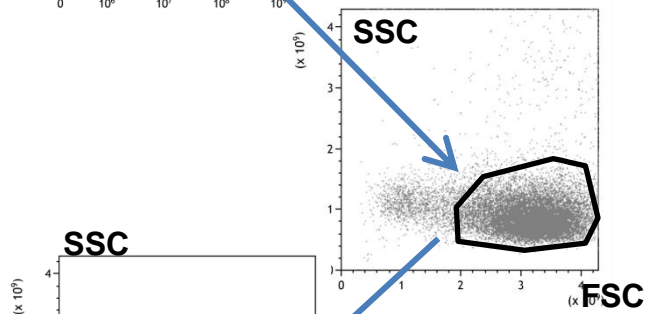
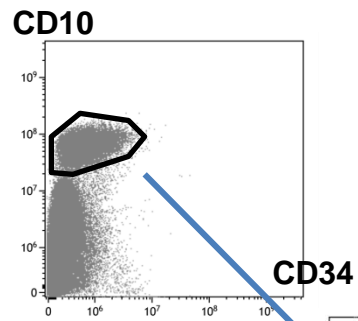

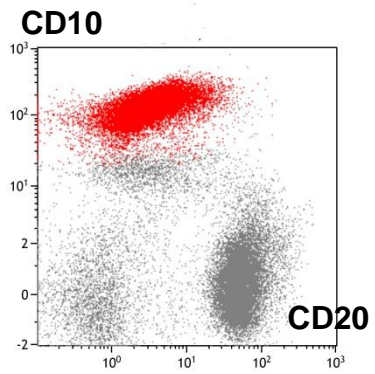
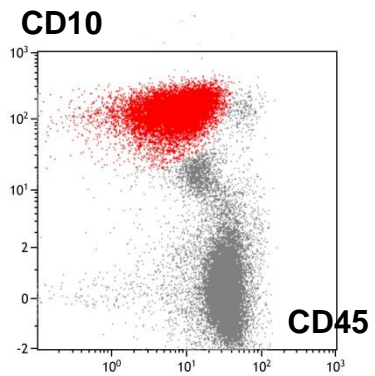
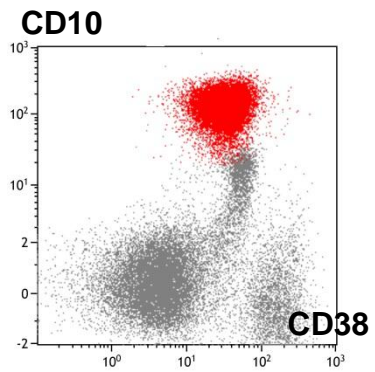


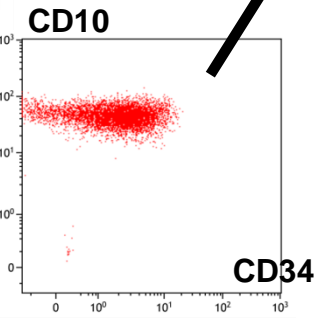
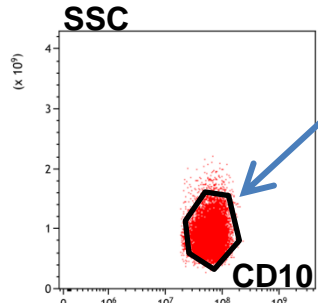
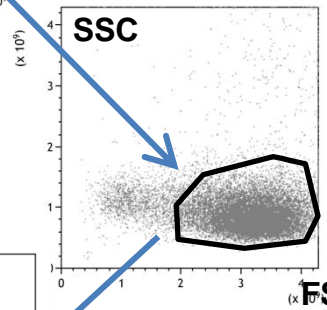
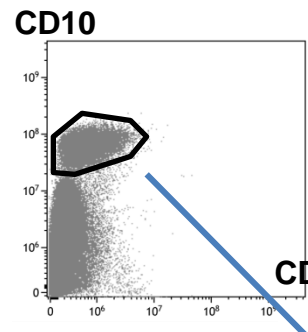

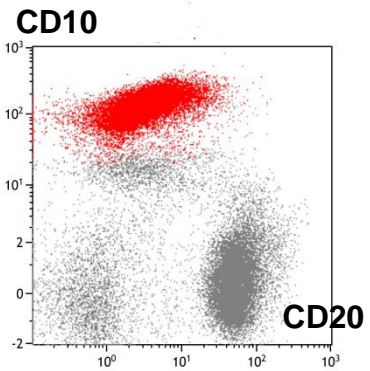
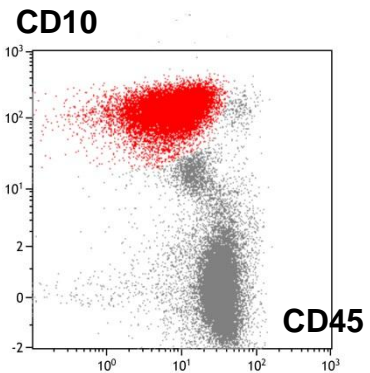
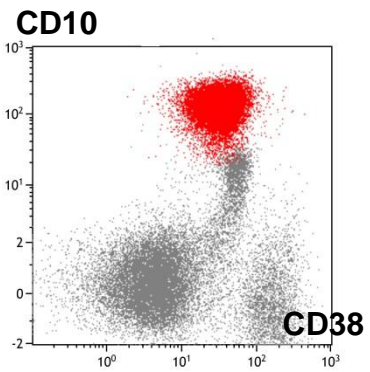


**SSC**

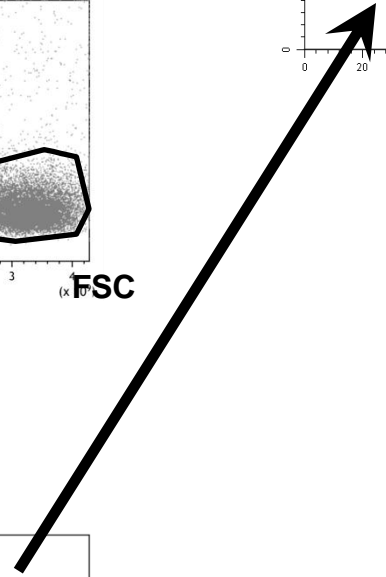
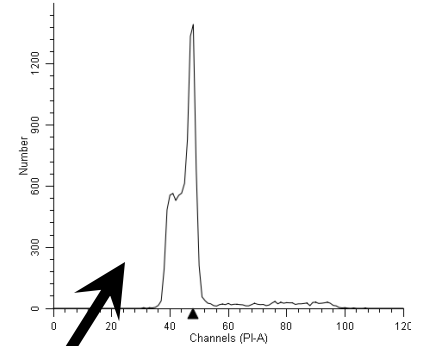


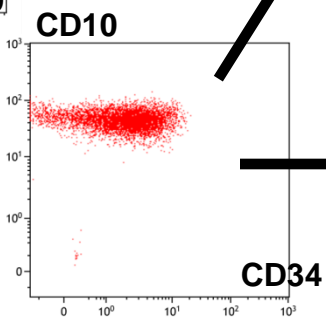
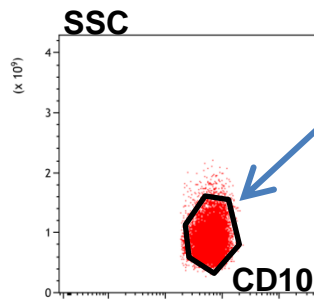
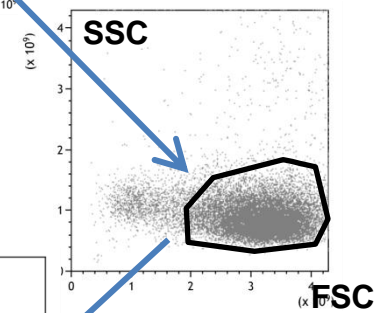
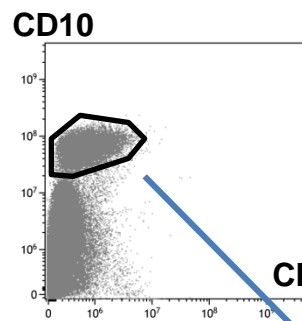

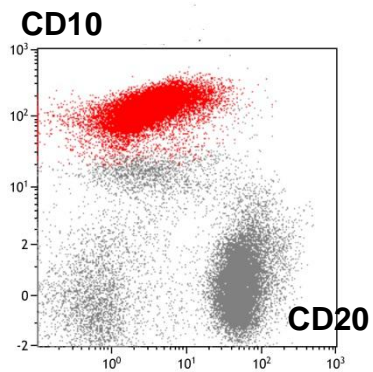
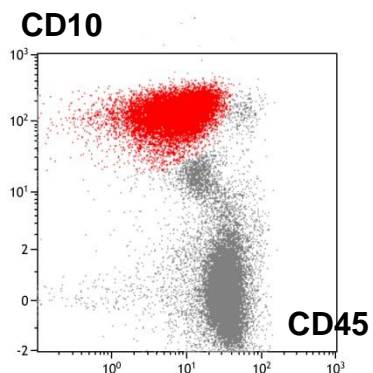
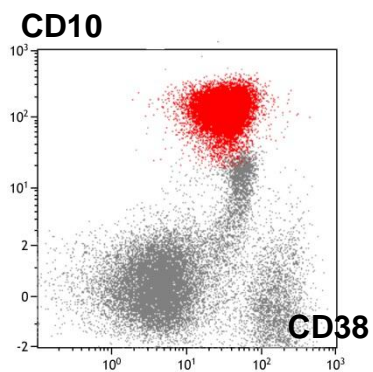




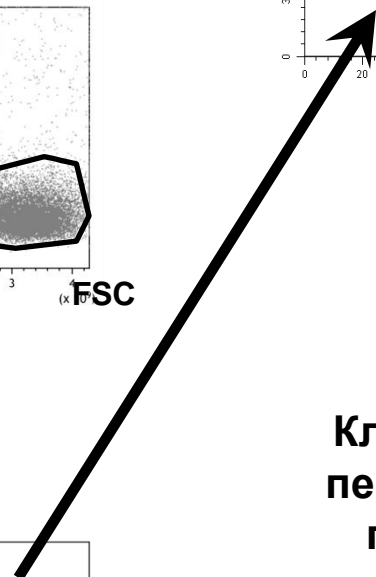
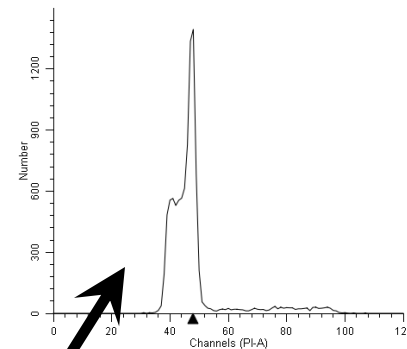


### ДНК-цитометрия

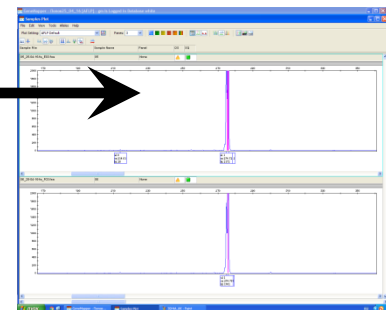




## ДНК-цитометрия

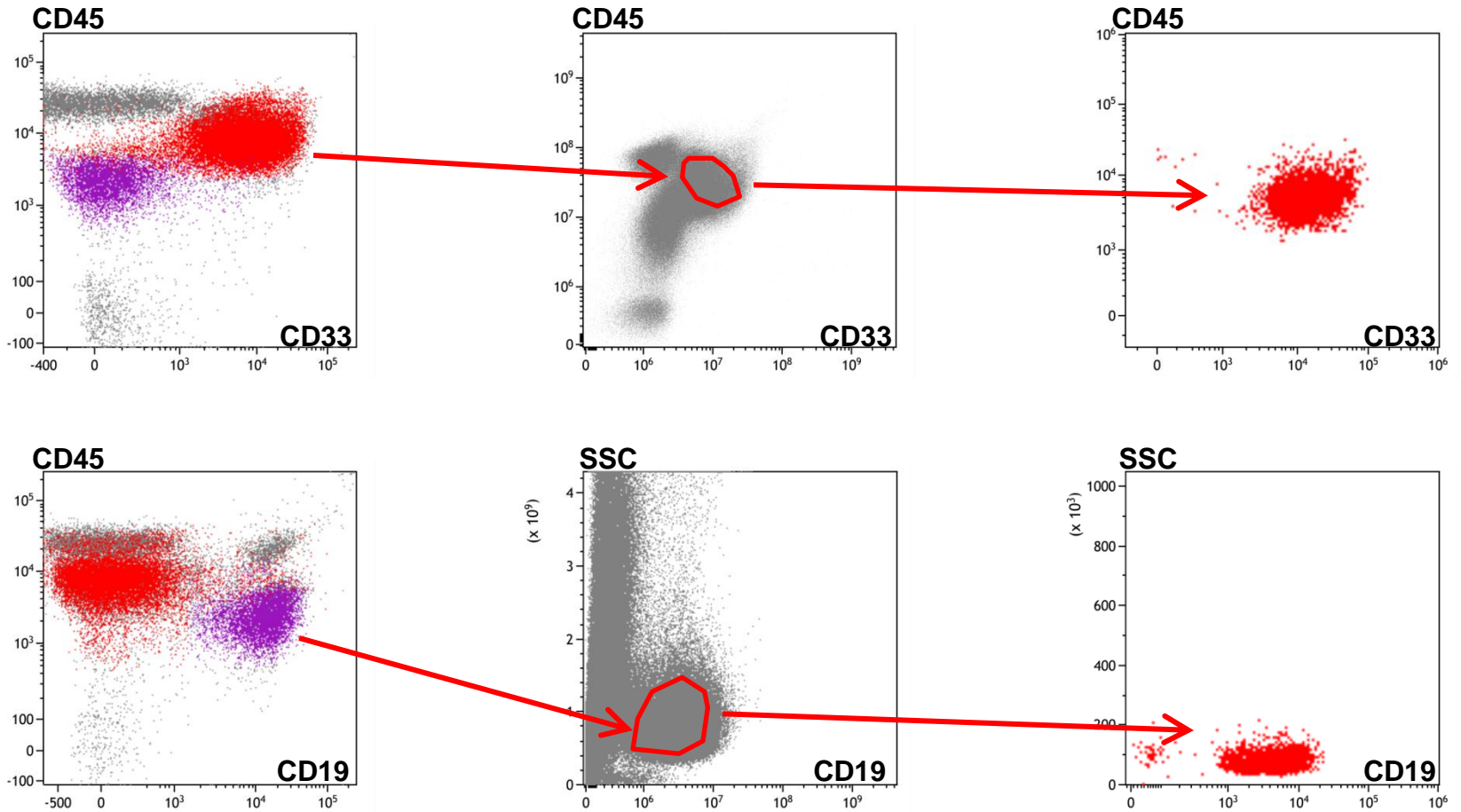


## Клональные перестройки генов *IgH*

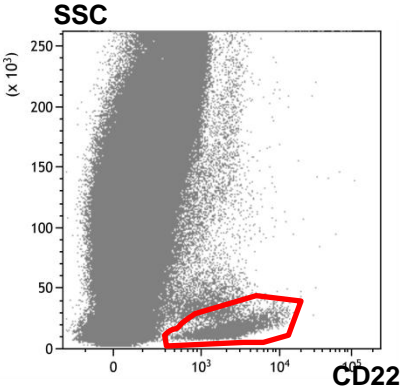


**Сортер ≠ цитометр**

# Сортер vs цитометр

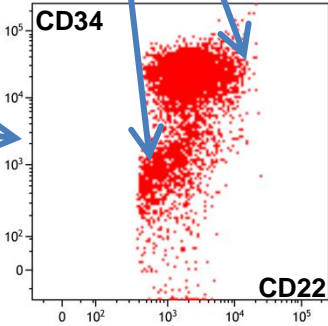
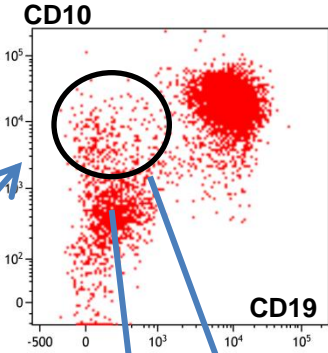
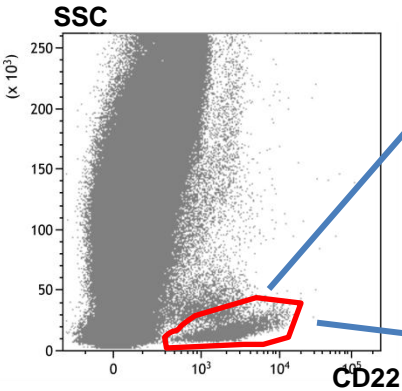


# FACS Canto II

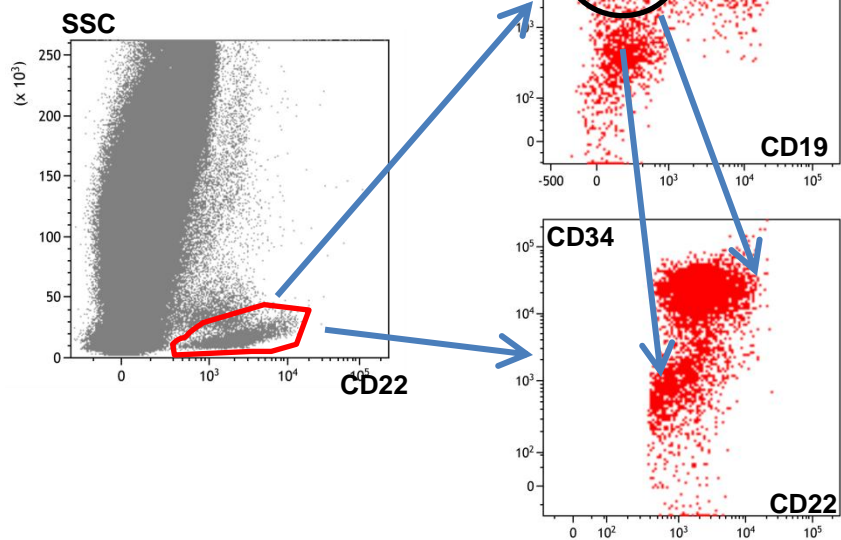




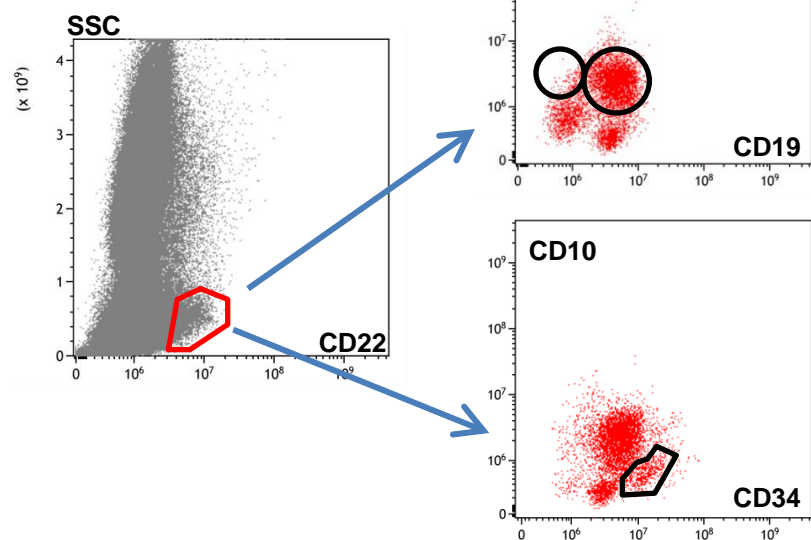
# FACS Canto II



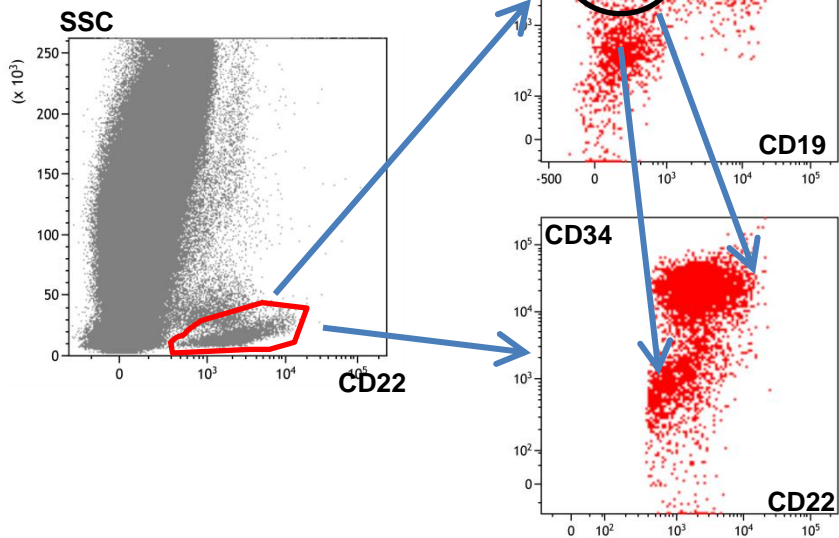
# FACS Canto II



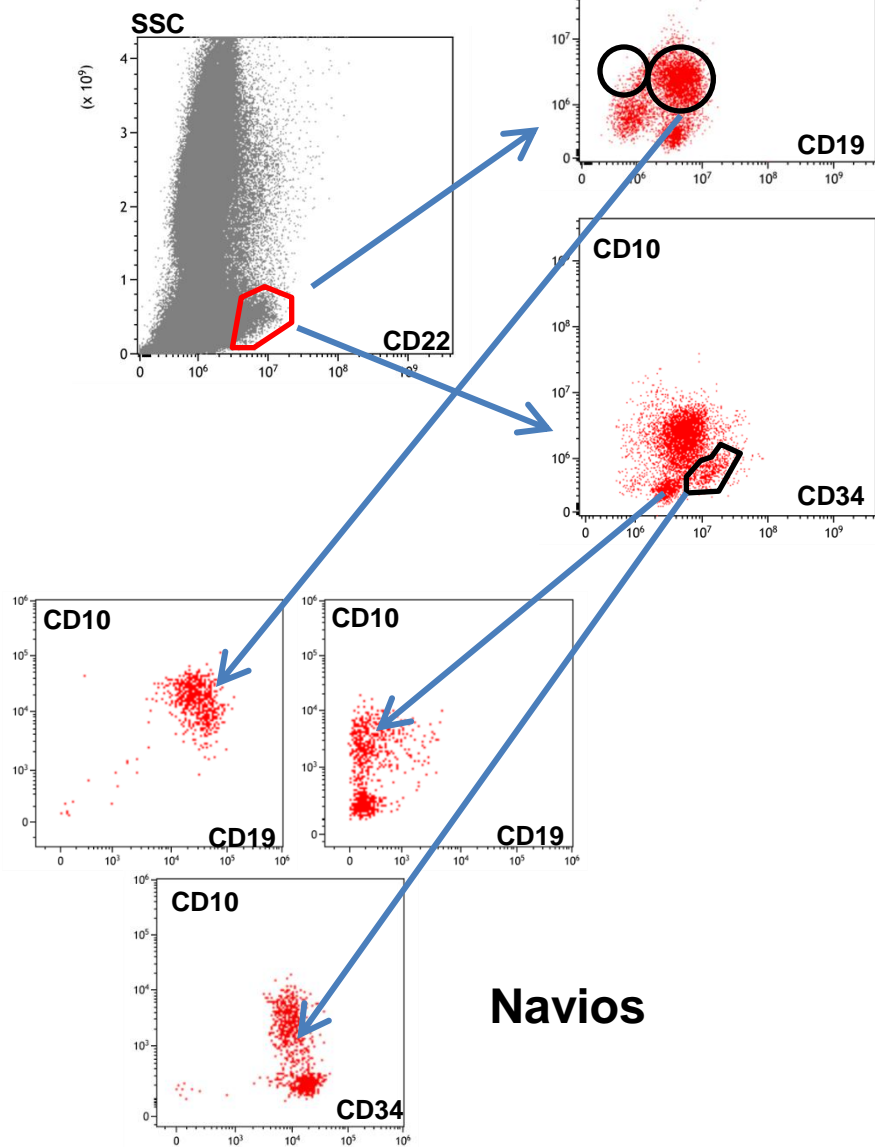
# MoFlo XDP



# FACS Canto II

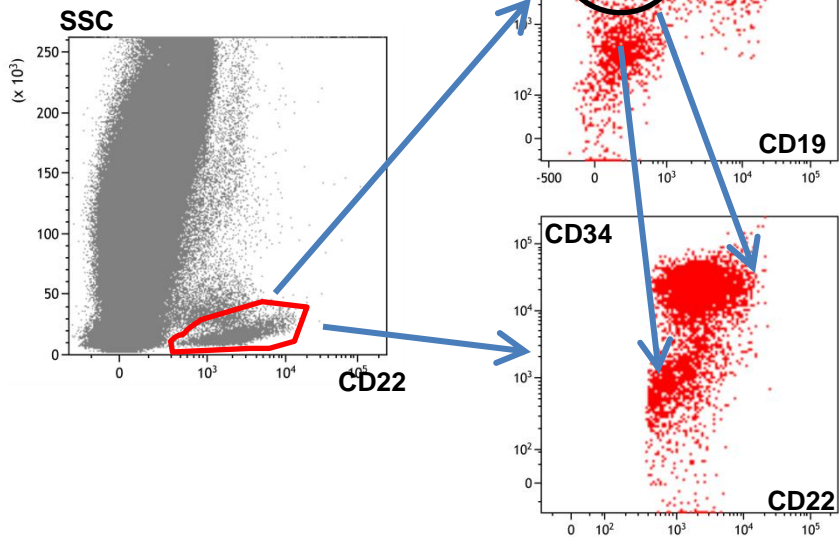


# MoFlo XDP

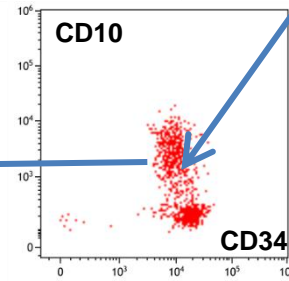
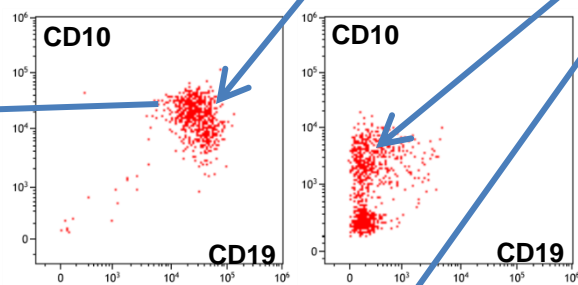
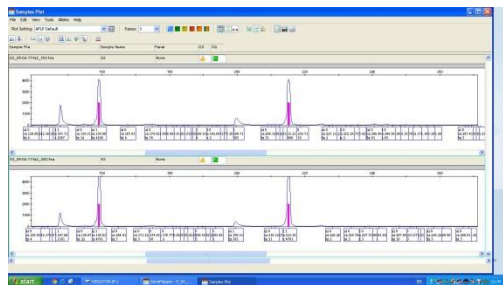
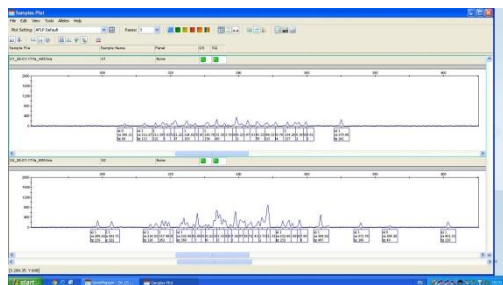
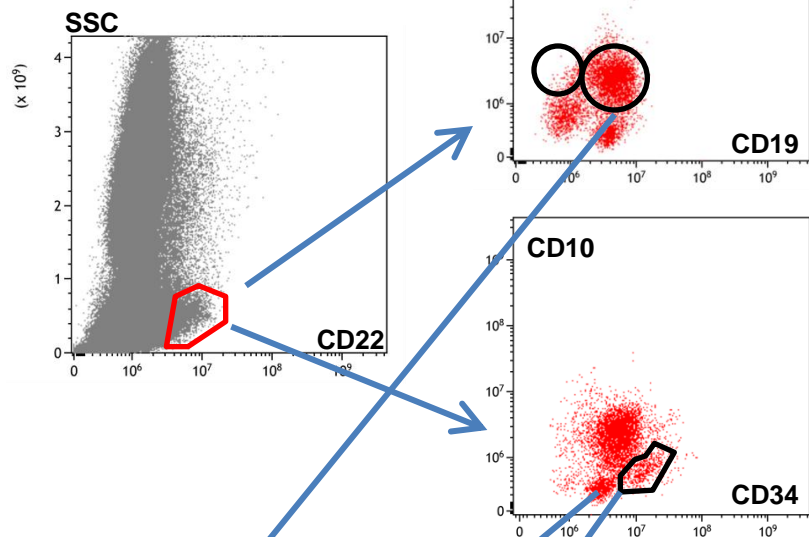


# Navios

# FACS Canto II



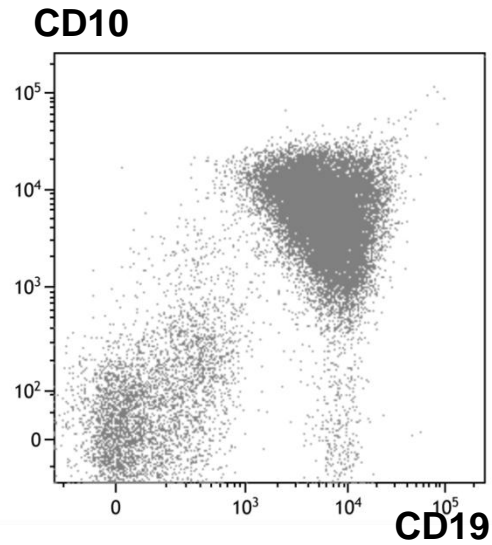
# MoFlo XDP



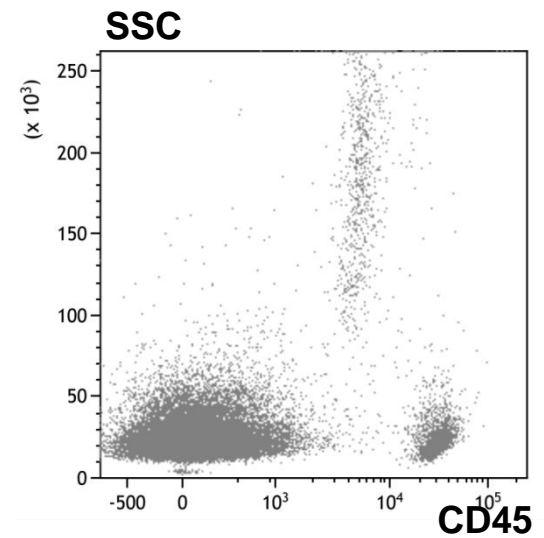
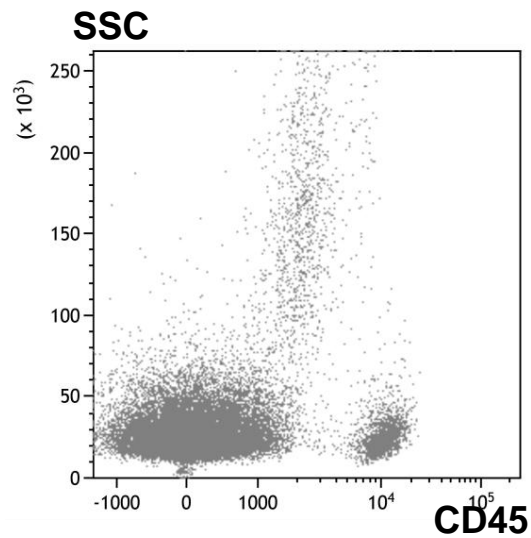
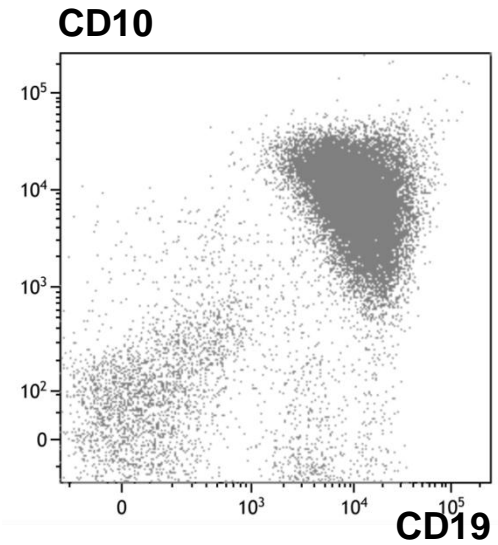
# Navios

# Сортер vs цитометр

## FACS Aria



## FACS Canto II





**Спасибо за внимание!**